



DATE PRESENTING CLINICAL SIGNS

3/4/2022 Lethargic, Anorexia and weight loss
Marked liver enzyme elevations;
Abdominal U/S: Pyloric and ICCJ have marked mural thickening w/ loss of layering.
Sample from ICCJ

INTERPRETED BY

L.D. McGill, DVM,
Ph.D, DACVP

CYTOLOGY SUBMISSION

Ileocecalcolic junction

OBSERVATIONS

Ileocecalcolic junction: Submitted are 7 excellent videos of moderate to excellent collections of cells from the ileocececocolic junction in Maddy. The majority of the cells are round cells, many of which are quite large and irregular. The round cells have minimal bluish gray cytoplasm. Many of the nuclei have prominent nucleoli. There are large numbers of smudge cells but there are many large irregular atypical round cells characteristic of atypical lymphoid cells. There are scattered neutrophils and rare macrophages.

PATIENT

Maddy Ashbaugh

SPECIES

Feline

INTERPRETATION OF THE FINDINGS & FURTHER RECOMMENDATIONS

Ileocecalcolic junction - Consistent with high-grade lymphoma

COMMENTS

BREED

The cellularity in these excellent videos is most characteristic of a high-grade lymphoma in Maddy. The cellularity could be B or T-cell lymphoma. Degeneration and inflammation are present but minimal and secondary. Immunophenotyping for the specific cell type may be beneficial in prognosis. It is not as prognostic in the cat as in the dog. T-cell lymphoma is not as positive for treatment in the cat. Due to the cell type in this excellent collection, an unfavorable prognosis is expected in Maddy.

DSH

SEX

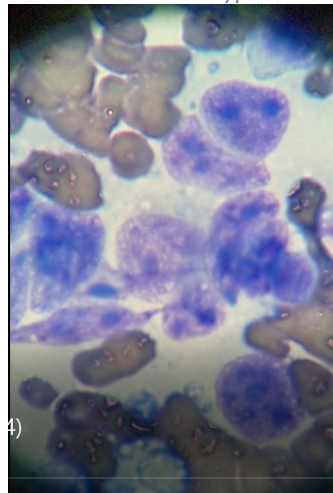
Female spayed

AGE

12y

WEIGHT

6.5



HOSPITAL NAME

Franklin Animal Clinic

Image shows some of the atypical lymphoid cells collected from Maddy. Note the multiple nucleoli.

REFERRING VET

Dr. Doverspike

The information and recommendations provided are based on the images presented by the referring veterinarian. No evaluation can be communicated regarding pathology that was not visible in the image/video clips provided.

INVOICE NUMBER

682

Thank you for this referral. If the clinical or image interpretation does not parallel your findings or if I can be of any further assistance please contact me.



DATE

3/4/2022

L.D. McGill, DVM, Ph.D., DACVP
8288 Top of the World Drive
Cottonwood Heights, UT 84121
ldmcgill.vetpath@gmail.com
cell: 801-865-1220

INTERPRETED BY

L.D. McGill, DVM,
Ph.D., DACVP

PATIENT

Maddy Ashbaugh

SPECIES

Feline

BREED

DSH

SEX

Female spayed

AGE

12y

WEIGHT

6.5

HOSPITAL NAME

Franklin Animal Clinic

REFERRING VET

Dr. Doverspike

INVOICE NUMBER

682