

DATE PRESENTING CLINICAL SIGNS

3/30/22 Hx of proteinuria and elevated Alk Phos, lethargic / ADR
Albumin 2.6, Alk Phos 234, Chole 564, Amylase 1779, PrecisionPSL 173, Neut 84%, Lymphocytes 9%, Eos 10%, Abs Neut 13020, Abs Monocytes 930

INTERPRETED BY CYTOLOGY SUBMISSION

L.D. McGill, DVM,
Ph.D, DACVP

FNA of Spleen

PATIENT

Maisie Spellman

OBSERVATIONS

Spleen: Submitted are 8 excellent videos of moderate collections of cells from the spleen in Maisie. The cellularity is mixed. The most prominent cellularity consists of neutrophils with scattered macrophages and many small mature lymphocytes. Nucleated RBCs are present. The majority of the change supports chronic inflammation. RBCs are prominent.

INTERPRETATION OF THE FINDINGS & FURTHER RECOMMENDATIONS

Spleen - Pyogranulomatous inflammation with nonspecific cellular collections

SPECIES

Canine

COMMENTS

The changes in this cellular collection supports chronic inflammation in the spleen. This could be leaking from any organ in the abdominal cavity including the pancreas, intestine or other organs. It could also be primary. In this instance it appears to be due to chronic inflammation which could be involved in bacterial infection or other types of changes. There is no suggestion of malignancy in this collection. A guarded prognosis is warranted since the underlying cause is not identified.

BREED

Lab Mix

SEX

FS

AGE

11yrs

WEIGHT

71.9#

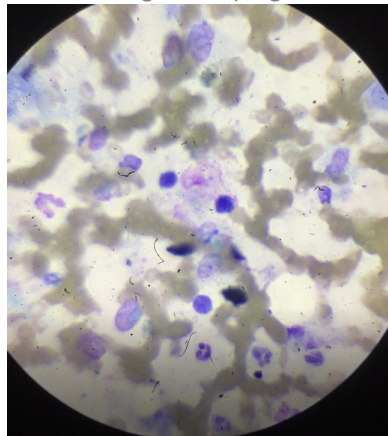


Image shows neutrophils with macrophages and a few small lymphocytes collected from the spleen in Maisie. Malignant characteristics are not identified.

HOSPITAL NAME

ACC Flanders

The information and recommendations provided are based on the images presented by the referring veterinarian. No evaluation can be communicated regarding pathology that was not visible in the image/video clips provided.

REFERRING VET

Dr. Hallihan

Thank you for this referral. If the clinical or image interpretation does not parallel your findings or if I can be of any further assistance, please contact me.

L.D. McGill, DVM, Ph.D., DACVP

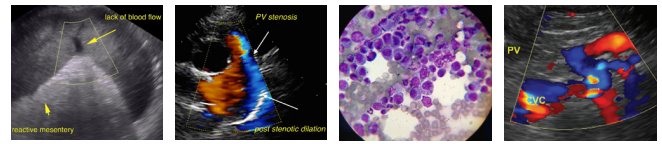
8288 Top of the World Drive
Cottonwood Heights, UT 84121

ldmcgill.vetpath@gmail.com

cell: 801-865-1220

INVOICE NUMBER

40493



DATE

3/30/22

INTERPRETED BY

L.D. McGill, DVM,
Ph.D, DACVP

PATIENT

Maisie Spellman

SPECIES

Canine

BREED

Lab Mix

SEX

FS

AGE

11yrs

WEIGHT

71.9#

HOSPITAL NAME

ACC Flanders

REFERRING VET

Dr. Hallihan

INVOICE NUMBER

40493