



DATE PRESENTING CLINICAL SIGNS

3/30/22

Hx of several day duration of ascites. Currently on benazapril, spironolactone, and furosemide. Had HW disease earlier in life. Fluid wave ballotted. abdominal and cardiac ultrasound submitted tto sonopath. FNA of ascites revealed serosanguineous fluid - flocculant in nature. TP - 3.5

INTERPRETED BY

L.D. McGill, DVM,
Ph.D, DACVP

CYTOLOGY SUBMISSION
Abdominal fluid

PATIENT

Bridget Klaus

OBSERVATIONS

Abdominal fluid: Submitted are 14 images of cells collected from the abdominal fluid in Adrienne. The cellularity is minimal. There are scattered RBCs and scattered neutrophils and eosinophils. Rare lymphocytes were identified. No specific etiologic agents are identified. There is no suggestion of malignant characteristics.

INTERPRETATION OF THE FINDINGS & FURTHER RECOMMENDATIONS

SPECIES Abdominal fluid - Minimally cellular collection with erythrocytes and mild suppurative inflammation.

Canine

COMMENTS

The cellularity is minimal but most suggestive of some type of cardiovascular abnormality. There is no suggestion of sepsis or malignancy. There is mild inflammation but this can be secondary to fluid buildup alone. Continued evaluation for cardiovascular disease processes including heart disease is encouraged. It could also be centered in the abdominal region. Chronic liver disease could explain this type of fluid collection. A guarded prognosis is warranted until the underlying cause for this fluid buildup can be identified.

BREED

Airdale

SEX

Female Spayed

AGE

12y

WEIGHT

65 lbs

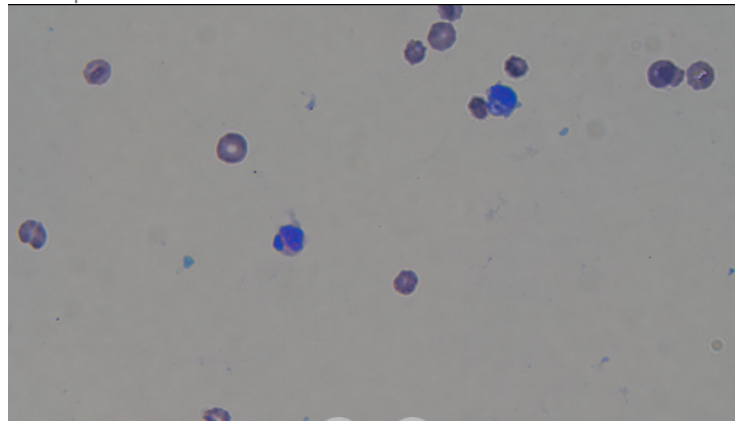


Image shows many RBCs with a neutrophil and eosinophil collected from Adrienne. This cellularity is minimal.

HOSPITAL NAME

Torch Lake Veterinary
Clinic

REFERRING VET

Dr. Waffle

The information and recommendations provided are based on the images presented by the referring veterinarian. No evaluation can be communicated regarding pathology that was not visible in the image/video clips provided.

Thank you for this referral. If the clinical or image interpretation does not parallel your findings or if I can be of any further assistance please contact me.

INVOICE NUMBER

702



DATE L.D. McGill, DVM, Ph.D., DACVP

3/30/22
8288 Top of the World Drive
Cottonwood Heights, UT 84121
ldmcgill.vetpath@gmail.com
cell: 801-865-1220

INTERPRETED BY

L.D. McGill, DVM,
Ph.D, DACVP

PATIENT

Bridget Klaus

SPECIES

Canine

BREED

Airdale

SEX

Female Spayed

AGE

12y

WEIGHT

65 lbs

HOSPITAL NAME

Torch Lake Veterinary
Clinic

REFERRING VET

Dr. Waffle

INVOICE NUMBER

702