



DATE PRESENTING CLINICAL SIGNS

3/29/23

Irregular large(35mm), soft somewhat fluctuating , SQ mass. On caudal-ventral abdomen of unknown duration. Appears to be attached to abdominal walls. On ultrasound abdominal wall is intact. Mass is echoic, slightly irregular.

INTERPRETED BY CYTOLOGY SUBMISSION

L.D. McGill, DVM, Ph.D,
DACVP

Subcutaneous mass

OBSERVATIONS

Subcutaneous mass: Submitted are 2 excellent videos of minimal nucleated cellular collections from the subcutaneous mass on Shoo Shoo. Where there are packets of cells, they are spindloid to polyhedral in shape. They demonstrate anisocytosis and anisokaryosis. The majority of the fields have no cells or have some red blood cells. There are scattered individualized cells. These spindloid to polyhedral cells demonstrate minimal characteristics of malignancy.

PATIENT

Shoo Shoo Stevenson

INTERPRETATION OF THE FINDINGS & FURTHER RECOMMENDATIONS

SPECIES

Subcutaneous mass - Minimal numbers of cells suggestive of soft tissue sarcoma.

Feline

COMMENTS

There are minimal numbers of cells in this collection but the ones that are present suggests the likelihood of a soft tissue sarcoma. Wide excision of these lesions is encouraged. Cytologically there is a concern about the potential of a spindle cell tumor that could recur and invade locally. Metastasis of these lesions may occur but it is uncommon. Local recurrence is common. A guarded prognosis is warranted due to the potential of local recurrence. Wide excision with at least 2 cm margins is recommended but this is not always possible.

BREED

DSH

SEX

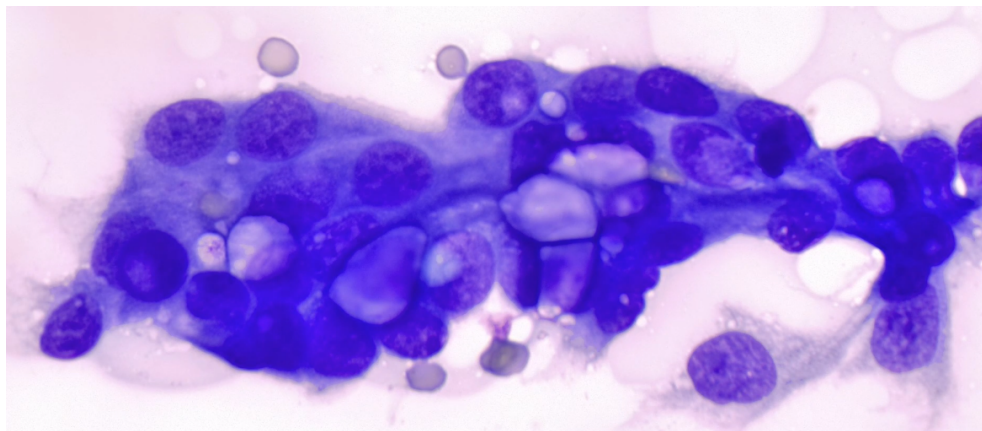
Female Spayed

AGE

12y

WEIGHT

7#



HOSPITAL NAME

Image shows representative cells collected from the subcutaneous mass on Shoo Shoo. Note the variable sized nuclei and polyhedral to spindloid appearance of the cells.

Rotterdam Veterinary
Hospital

REFERRING VET

Dr. St. Sir

The information and recommendations provided are based on the images presented by the referring veterinarian. No evaluation can be communicated regarding pathology that was not visible in the image/video clips provided.

Thank you for this referral. If the clinical or image interpretation does not parallel your findings or if I can be of any further assistance please contact me.

INVOICE NUMBER

925



DATE

3/29/23

L.D. McGill, DVM, Ph.D., DACVP

8288 Top of the World Drive
Cottonwood Heights, UT 84121
ldmcgill.vetpath@gmail.com
cell: 801-865-1220

INTERPRETED BY

L.D. McGill, DVM, Ph.D,
DACVP

PATIENT

Shoo Shoo Stevenson

SPECIES

Feline

BREED

DSH

SEX

Female Spayed

AGE

12y

WEIGHT

7#

HOSPITAL NAME

Rotterdam Veterinary
Hospital

REFERRING VET

Dr. St. Sir

INVOICE NUMBER

925