



**DATE PRESENTING CLINICAL SIGNS**

3/29/23

Anorexia, occasional vomiting, icteric, afebrile. Weight loss over past few months. Clotting profile WNL. FNA done of liver. PE: QAR/depressed.

**INTERPRETED BY**

L.D. McGill, DVM, Ph.D,  
DACVP

ALP 1993, ALT > 2000, TBili 5.4, K+ 3.6, serum icteric. Lepto titers all negative @ < 1:100. AUS (report attached): Hepatopathy (possibly acute on chronic), no evidence of EHBDO, mild segmental to generalized enteropathy with mild lymphadenopathy.

**CYTOLOGY SUBMISSION**

Liver

**PATIENT**

Penny Bozeman

**OBSERVATIONS**

Liver: Submitted are 7 excellent videos of cells collected from the liver in Penny. The cellularity consists of a few packets of hepatocytes. The hepatocytes demonstrate mild vacuolization. This is scattered throughout the hepatocytes available to evaluate. Interspersed in the red blood cells surrounding these hepatocytes are aggregates of lymphocytes and neutrophils. The lymphocytes are intermediate to larger lymphocytes and the neutrophils are inflammatory in nature. The lymphocytes are not effacing the liver tissue.

**SPECIES**

Canine

**INTERPRETATION OF THE FINDINGS & FURTHER RECOMMENDATIONS**

Liver - Hepatocellular vacuolization with increased numbers of lymphocytes and neutrophils in the collection..

**BREED**

Coonhound

**COMMENTS**

The hepatocellular vacuolization supports metabolic liver disease which can be secondary to many different conditions. This can be secondary to pancreatitis, enteritis or other abdominal organ changes. There is no suggestion of malignancy but there is an increased number of lymphocytes and neutrophils in the collection. This could suggest a lymphocytic cholangiohepatitis or other inflammatory process in the liver. I'm always concerned about the potential of the liver responding secondarily to other abdominal organ changes. Pancreatitis is still a condition I would consider particularly with increased bile in the blood. This could occur secondary to swelling around the common bile duct going through the pancreas. Treatment for chronic inflammatory process such as pancreatitis is encouraged. A guarded prognosis is warranted since the underlying cause is not identified as of this time.

**SEX**

Female Spayed

**AGE**

12y

**WEIGHT**

48 lbs

**HOSPITAL NAME**

Scanvet

**REFERRING VET**

Dr. Barengo

**INVOICE NUMBER**

926



**DATE**

3/29/23

**INTERPRETED BY**

L.D. McGill, DVM, Ph.D,  
DACVP

**PATIENT**

Penny Bozeman

**SPECIES**

Canine

**BREED**

Coonhound

**SEX**

Female Spayed

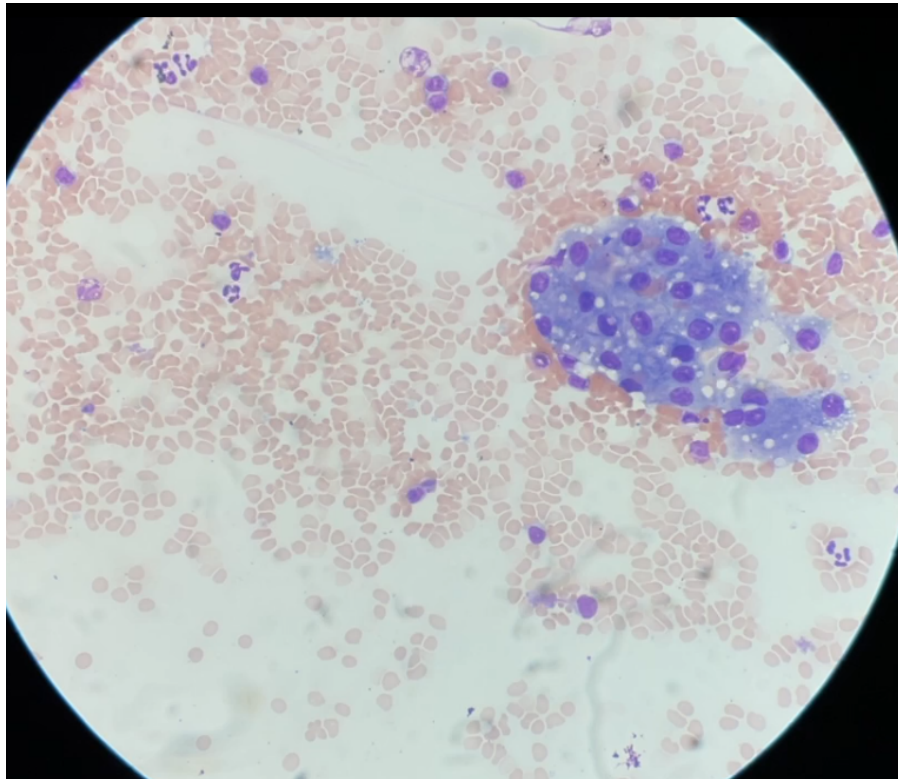


Image shows hepatocytes with vacuolization in the collection from Penny. Note the prominent lymphocytes and neutrophils in the surrounding RBCs.

**AGE**

12y

The information and recommendations provided are based on the images presented by the referring veterinarian. No evaluation can be communicated regarding pathology that was not visible in the image/video clips provided.

**WEIGHT**

48 lbs

Thank you for this referral. If the clinical or image interpretation does not parallel your findings or if I can be of any further assistance please contact me.

**HOSPITAL NAME**

Scanvet

**L.D. McGill, DVM, Ph.D., DACVP**  
8288 Top of the World Drive  
Cottonwood Heights, UT 84121  
ldmcgill.vetpath@gmail.com  
cell: 801-865-1220

**REFERRING VET**

Dr. Barengo

**INVOICE NUMBER**

926