

DATE PRESENTING CLINICAL SIGNS

3/29/22

Patient History: Elevated liver enzymes, vomiting, diarrhea, anorexia. CPL normal. Current meds: Cerenia, Soloxine
U/S findings: The prostate was mildly enlarged and mineralized. The prostate measured 1.82 cm with mild, enhanced, surrounding mesentery. The prostate did not quite form a mass, yet I am concerned about emerging carcinoma.

INTERPRETED BY

L.D. McGill, DVM,
Ph.D, DACVP

Recommendations: FNA of the prostate with a minor potential for trailing or traumatic catheterization could be considered. If the prostate is negative for neoplasia, then splenectomy is indicated as long as chest radiographs are free of evident pathology.

WBC 5.6 (6 L); Neut 3.58 (3.62 L); BUN 8 (9 L); Chol 340 (310 H); ALT 363 (120 H); ALP 612 (140 H); GGT 17 (14 H)

PATIENT CYTOLOGY SUBMISSION

Dexter Carrecino

FNA of Prostate

OBSERVATIONS

SPECIES

Canine

Prostate: Submitted are 3 videos of minimal cellular collections from the prostate in Dexter. I had trouble identifying specific cells. The majority of the collection is degenerate debris, protein and possibly some lipid. There are no changes that would support malignancy or inflammation.

INTERPRETATION OF THE FINDINGS & FURTHER RECOMMENDATIONS

Prostate - Degenerate debris and nonspecific collection

BREED

Spaniel Mix

COMMENTS

With a minimal cellularity in this collection, neoplasia is likely not part of the process. This easily could be the result of an atrophied prostatic tissue with degenerate material and nonspecific change. There is no suggestion of infection or malignancy. The cellularity in this collection does not preclude the potential of having a successful splenectomy.

SEX

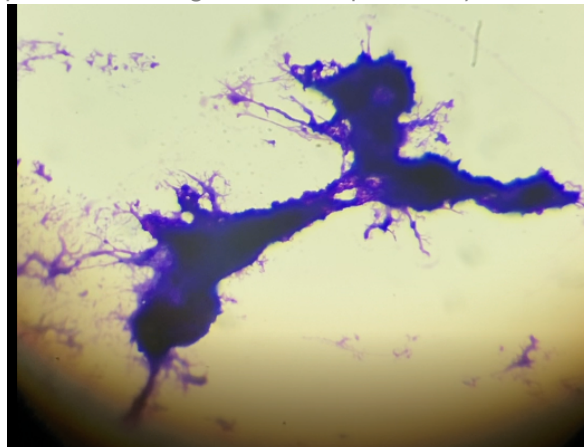
Male Neutered

AGE

10y

WEIGHT

61.5#



HOSPITAL NAME

Newton Veterinary
Hospital

Image shows some of the material collected from the prostate in Dexter. This is nonspecific.

The information and recommendations provided are based on the images presented by the referring veterinarian. No evaluation can be communicated regarding pathology that was not visible in the image/video clips provided.

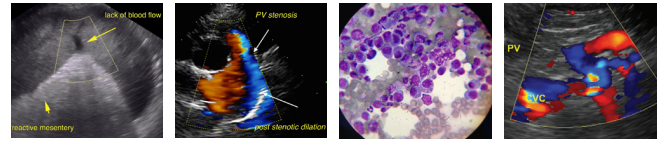
REFERRING VET

Dr. Kim

Thank you for this referral. If the clinical or image interpretation does not parallel your findings or if I can be of any further assistance, please contact me.

INVOICE NUMBER

40491



DATE L.D. McGill, DVM, Ph.D., DACVP
8288 Top of the World Drive
Cottonwood Heights, UT 84121
ldmcgill.vetpath@gmail.com
cell: 801-865-1220

INTERPRETED BY

L.D. McGill, DVM,
Ph.D., DACVP

PATIENT

Dexter Carrecino

SPECIES

Canine

BREED

Spaniel Mix

SEX

Male Neutered

AGE

10y

WEIGHT

61.5#

HOSPITAL NAME

Newton Veterinary
Hospital

REFERRING VET

Dr. Kim

INVOICE NUMBER

40491