



DATE PRESENTING CLINICAL SIGNS

3/28/22

Presented for fever, lethargy, elevated liver enzymes. Long history dietary sensitivities, mostly skin but recently diarrhea.

Meds: diatomaceous earth, probiotic, digestive enzymes
Diet: home cooked yam, white potato, Alaskan cod

INTERPRETED BY

L.D. McGill, DVM,
Ph.D, DACVP

-Presented to primary care this week and had ultrasound showing adrenal nodule;
-ALT ~ 500 on admit last night, decreased to 440 today

-Lepto and 4DX neg
-normal Low Dose Dex suppression by rDVM

-Temp 104.5 on admit

-Thoracic radiographs no obvious cause for fever (radiology interp through IDEXX)

PATIENT

Gus Dewalt

CYTOLOGY SUBMISSION

FNA of Liver

SPECIES

Canine

OBSERVATIONS

Liver: Submitted are 6 excellent videos of cells collected from the liver in Gus. There are scattered aggregates of hepatocytes but the major cellularity consists of massive numbers of neutrophils. There are scattered lymphocytes and macrophages in some of the videos but there are several videos that show extreme numbers of neutrophils. Many of these cells are degenerate and smudged. Bile canaliculi are identified between hepatocytes in some fields.

BREED

Dachshund

SEX

Male Neutered

INTERPRETATION OF THE FINDINGS & FURTHER RECOMMENDATIONS

Liver - Severe chronic suppurative inflammation suggesting abscess.

COMMENTS

The changes in this tissue support a severe suppurative reaction which is most likely a bacterial infection. I was unable to identify specific bacteria but they must be present. Hopefully a culture was taken from the collection. The changes are more severe than expected for leptospirosis and there certainly is no suggestion of neoplasia. This easily could be in ascending bacterial infection forming abscessation in the liver. The biliary canaliculi suggest obstruction there. The source could be the pancreas or the intestine. A guarded prognosis is warranted. The severity of the suppurative response causes me to be concerned about an unfavorable prognosis.

WEIGHT

8kg

HOSPITAL NAME

Animal Emergency Carel

REFERRING VET

Dr. Becky Callihan DVM

INVOICE NUMBER

40489



DATE

3/28/22

INTERPRETED BY

L.D. McGill, DVM,
Ph.D., DACVP

PATIENT

Gus Dewalt

SPECIES

Canine

BREED

Dachshund

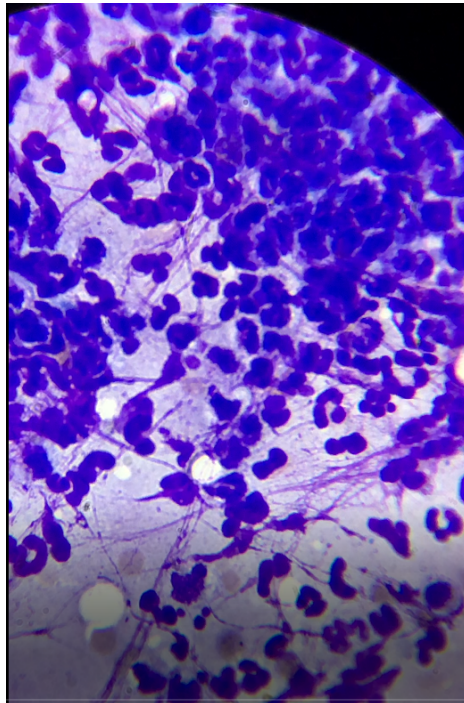


Image shows a field of massive numbers of neutrophils collected from the liver in Gus. There were other videos with these cells and others with slightly vacuolated hepatocyte.

SEX

Male Neutered

The information and recommendations provided are based on the images presented by the referring veterinarian. No evaluation can be communicated regarding pathology that was not visible in the image/video clips provided.

AGE

10yr

Thank you for this referral. If the clinical or image interpretation does not parallel your findings or if I can be of any further assistance, please contact me.

WEIGHT

8kg

L.D. McGill, DVM, Ph.D., DACVP
8288 Top of the World Drive
Cottonwood Heights, UT 84121
ldmcgill.vetpath@gmail.com
cell: 801-865-1220

HOSPITAL NAME

Animal Emergency Carel

REFERRING VET

Dr. Becky Callihan DVM

INVOICE NUMBER

40489