

**DATE PRESENTING CLINICAL SIGNS**

3/28/22 Swollen neck

**CYTOLOGY SUBMISSION**

FNA of Neck Mass

**INTERPRETED BY**

L.D. McGill, DVM,  
Ph.D, DACVP

**OBSERVATIONS**

Neck Mass: Submitted are 2 excellent videos of excellent collections of cells from the neck mass in Comet. The cellularity consists of large numbers of round cells that have round nuclei that are mainly 2 to 4 times the size of red blood cells. Many of these cells have prominent nucleoli. There is a narrow thin cytoplasm of bluish gray material. There are very few small lymphocytes and neutrophils. Scattered cells suggest early mitotic figures.

**PATIENT**

Comet Lemiux

**INTERPRETATION OF THE FINDINGS & FURTHER RECOMMENDATIONS**

Neck Mass - Consistent with High-grade Lymphoma

**SPECIES COMMENTS**

Canine

The cellularity is strongly suggestive of a high-grade lymphoma in Comet. The cellularity is extremely consistent with some smudge cells and degenerate debris. It is possible that this could be a localized indolent lymphoma and excision of the mass may be beneficial in therapy. This could prolong the life in Comet. If other lymph nodes are involved, then this would not be in indolent lymphoma. If chemotherapy is contemplated, immunophenotyping of the cells in this collection may be beneficial to identify cell type. This information may contribute to the prognosis. These slides may be submitted for PARR testing or biopsy and immunohistochemistry staining can be undertaken. Re-collection for flow cytometry evaluation will be required if that testing is desired. You may wish to contact the laboratory to confirm the sample required for flow cytometry. A guarded to unfavorable prognosis is warranted following evaluation of this collection.

**BREED**

mix

**SEX**

Male Neutered

**AGE**

9y

**WEIGHT**

60

**HOSPITAL NAME**

Bayshore Veterinary  
Hospital

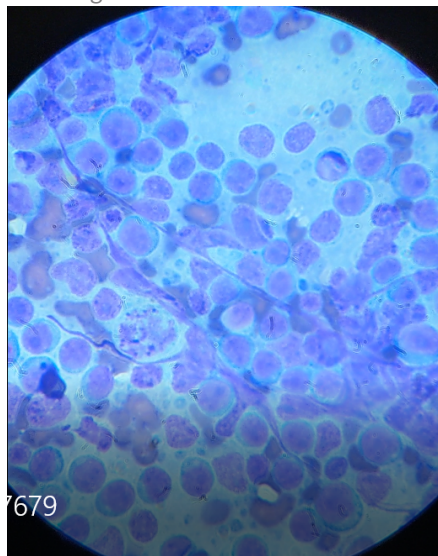


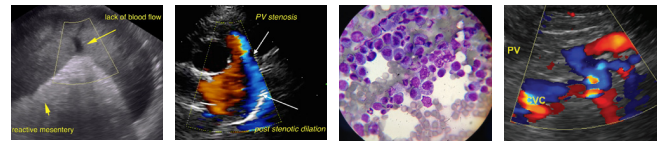
Image shows 1 of the "blue" fields with atypical lymphoid cells collected from the neck mass in Comet. Note the prominent nucleoli.

**REFERRING VET**

Dr. Hunt

**INVOICE NUMBER**

40490



**DATE** 3/28/22 The information and recommendations provided are based on the images presented by the referring veterinarian. No evaluation can be communicated regarding pathology that was not visible in the image/video clips provided.

**INTERPRETED BY** L.D. McGill, DVM, Ph.D., DACVP Thank you for this referral. If the clinical or image interpretation does not parallel your findings or if I can be of any further assistance, please contact me.

L.D. McGill, DVM,  
Ph.D., DACVP

**L.D. McGill, DVM, Ph.D., DACVP**  
8288 Top of the World Drive  
Cottonwood Heights, UT 84121  
ldmcgill.vetpath@gmail.com  
cell: 801-865-1220

**PATIENT** Comet Lemiux

**SPECIES**

Canine

**BREED**

mix

**SEX**

Male Neutered

**AGE**

9y

**WEIGHT**

60

**HOSPITAL NAME**

Bayshore Veterinary  
Hospital

**REFERRING VET**

Dr. Hunt

**INVOICE NUMBER**

40490