



**DATE PRESENTING CLINICAL SIGNS**

3/25/22

Delayed gastric emptying, suspect secondary to pancreatitis. US showed pancreatitis and undefined 2.0cm structure medial to the spleen - pancreatic necrosis vs accessory spleen. FNA performed.  
HCT 63%, abnormal CPL 46.5

**INTERPRETED BY**

L.D. McGill, DVM,  
Ph.D, DACVP

**CYTOLOGY SUBMISSION**

Pancreatic mass

**PATIENT**

Woody Yates

**OBSERVATIONS**

Pancreatic mass: Submitted are 4 excellent videos of moderate collections of cells from the pancreatic mass in Woody. The cellularity in the collection is mixed. There are many neutrophils scattered throughout with macrophages and spindloid cells. There are a few lymphocytes but they appear to be mature. Spindloid cells are prominent with macrophages and some of these cells are rather large. Necrosis and inflammation appear to be the major process.

**SPECIES**

Canine

**INTERPRETATION OF THE FINDINGS & FURTHER RECOMMENDATIONS**

Pancreatic mass - Pyogranulomatous inflammation with necrosis and some suggestion of fibrosis.

**BREED**

French Bulldog

**COMMENTS**

The cellularity supports chronic inflammation and necrosis. I am unable to identify changes that would support neoplasia. There is certainly no suggestion of lymphoma. Due to the inflammation and necrosis, I suspect that this is a localized area pancreatitis with degeneration. There are some cases of neoplasia that have marked necrosis and inflammation in the center. This would be an alternative possibility in this case but there are no neoplastic cells to make that diagnosis. If problems continue, then exploratory and excision of the mass may be required both for therapy and for diagnosis.

**SEX**

Male Neutered

**AGE**

4y

**WEIGHT**

24 lbs

**HOSPITAL NAME**

Basking Ridge Animal  
Hospital

**REFERRING VET**

Dr. Vlassin

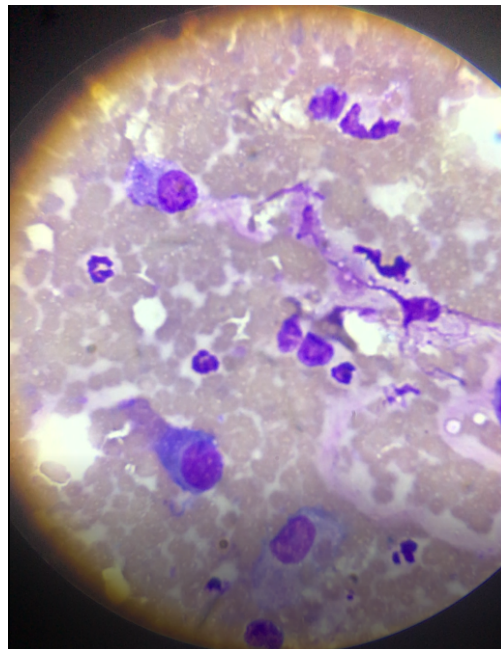


Image shows a hemorrhagic collection with inflammation and necrosis. Neutrophils are prominent in this collection from Woody.

**INVOICE NUMBER**

700



**DATE**

3/25/22

The information and recommendations provided are based on the images presented by the referring veterinarian. No evaluation can be communicated regarding pathology that was not visible in the image/video clips provided.

**INTERPRETED BY**

L.D. McGill, DVM,  
Ph.D, DACVP

Thank you for this referral. If the clinical or image interpretation does not parallel your findings or if I can be of any further assistance please contact me.

**PATIENT**

Woody Yates

L.D. McGill, DVM, Ph.D., DACVP  
8288 Top of the World Drive  
Cottonwood Heights, UT 84121  
ldmcgill.vetpath@gmail.com  
cell: 801-865-1220

**SPECIES**

Canine

**BREED**

French Bulldog

**SEX**

Male Neutered

**AGE**

4y

**WEIGHT**

24 lbs

**HOSPITAL NAME**

Basking Ridge Animal  
Hospital

**REFERRING VET**

Dr. Vlassin

**INVOICE NUMBER**

700