



DATE PRESENTING CLINICAL SIGNS

3/25/22 Enlarged LN's in neck. Also weight loss.
VERY BAD Dental Dz. Mandibular LN's markedly enlarged; However all peripheral LN's Moderatel enlarged (Submitted sample from Popliteal and Pre-Scapular LN's.
Lab work normal except sl elevated BUN

INTERPRETED BY

L.D. McGill, DVM,
Ph.D, DACVP

CYTOLOGY SUBMISSION

Lymph node

OBSERVATIONS

Lymph node: Submitted are 5 excellent videos of excellent collections of cells from the lymph node in Molly. The cellularity consists of large numbers of round cells that are almost all lymphoid cells. Many of the cells have large nuclei that are 2 to 6 times the size of red blood cells. These cells have prominent to multiple nucleoli. Some of the nucleoli are quite large. There are scattered neutrophils and a very few small mature lymphocytes in the collection. Scattered mitotic figures are identified.

SPECIES INTERPRETATION OF THE FINDINGS & FURTHER RECOMMENDATIONS

Canine Lymph node - Consistent with high-grade lymphoma.

COMMENTS

The cellularity is strongly suggestive of a high-grade lymphoma. The lymphoid cells are quite large and irregular and atypical in this collection from Molly. The neoplastic cells appear to be greater than 70 to 80% of the cells. If chemotherapy is contemplated, immunophenotyping of the cells in this collection may be beneficial to identify cell type. This information may contribute to the prognosis. These slides may be submitted for PARR testing or biopsy and immunohistochemistry staining can be undertaken. Re-collection for flow cytometry evaluation will be required if that testing is desired. You may wish to contact the laboratory to confirm the sample required for flow cytometry. An unfavorable prognosis is expected in the long run in my opinion. Some high-grade lymphomas in the dog will respond to chemotherapy, at least for a period of time.

BREED

Chihuahua

SEX

Female Spayed

AGE

13y

WEIGHT

11 lbs

HOSPITAL NAME

Franklin Animal Clinic

REFERRING VET

Dr. Doverspike

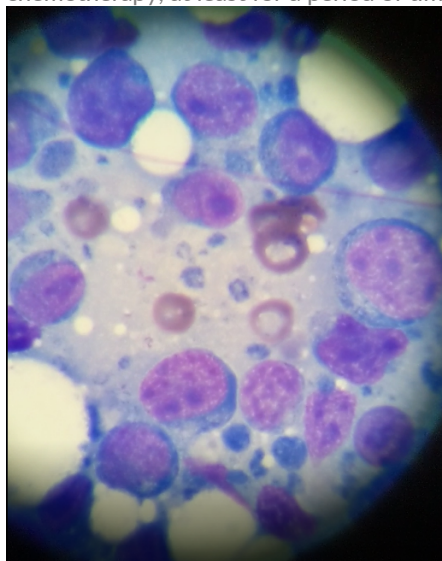


Image shows a group of large lymphoid cells collected from Molly. Note the prominent nucleoli and the nuclei that are 4-6 times the size of RBCs.

INVOICE NUMBER

699



DATE 3/25/22 The information and recommendations provided are based on the images presented by the referring veterinarian. No evaluation can be communicated regarding pathology that was not visible in the image/video clips provided.

INTERPRETED BY L.D. McGill, DVM, Ph.D., DACVP Thank you for this referral. If the clinical or image interpretation does not parallel your findings or if I can be of any further assistance please contact me.

L.D. McGill, DVM,
Ph.D., DACVP

L.D. McGill, DVM, Ph.D., DACVP
8288 Top of the World Drive
Cottonwood Heights, UT 84121
ldmcgill.vetpath@gmail.com
cell: 801-865-1220

PATIENT

Molly Grove

SPECIES

Canine

BREED

Chihuahua

SEX

Female Spayed

AGE

13y

WEIGHT

11 lbs

HOSPITAL NAME

Franklin Animal Clinic

REFERRING VET

Dr. Doverspike

INVOICE NUMBER

699