



DATE PRESENTING CLINICAL SIGNS

3/24/23

1.2cm soft, mobile growth on right axilla.

CYTOLOGY SUBMISSION

Lipid mass

INTERPRETED BY

L.D. McGill, DVM, Ph.D,
DACVP

OBSERVATIONS

Right axillary mass: Submitted are 3 excellent videos and one image of cells collected from the right axillary mass on Zoey. The cellularity consists of a characteristic collection of adipocytes which are irregular in size and shape with scattered irregular nuclear characteristics. Some of the cells are small and slightly elongated. The adipocytes are irregular in size and shape. The nuclei are rounded with narrow well demarcated cell margins.

PATIENT

Zoey Behiri

INTERPRETATION OF THE FINDINGS & FURTHER RECOMMENDATIONS

Right axilla mass - Adipocyte proliferation suggestive of a lipoma or possible liposarcoma.

SPECIES COMMENTS

Canine

The cellularity is a characteristic proliferation of adipocytes in irregular patterns. There are some locations where the cells appear to be more proliferative than others. These locations suggest the likelihood of a liposarcoma. It is at least a lipoma in this collection but may be more aggressive. Wider excision of the mass is encouraged with the follow-up biopsy to confirm the specific nature of this adipocyte proliferation. Excision is the only means for therapy at this point. Consultation with an oncologist may be beneficial if further information supports a liposarcoma.

BREED

Goldendoodle

SEX

Female Spayed

AGE

9y

WEIGHT

61.5

HOSPITAL NAME

Rotterdam Veterinary Hospital

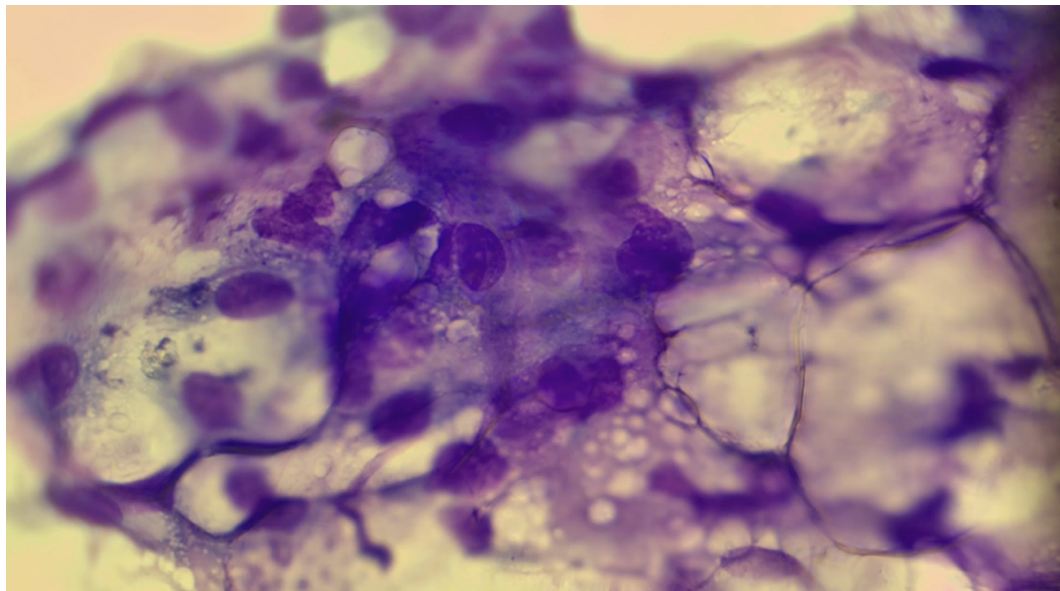


Image shows a group of adipocytes with anisocytosis collected from the right axilla mass on Zoey. Note the smaller cells with round to elongated nuclei in this collection.

REFERRING VET

Dr. Scarpinato

The information and recommendations provided are based on the images presented by the referring veterinarian. No evaluation can be communicated regarding pathology that was not visible in the image/video clips provided.

INVOICE NUMBER

922

Thank you for this referral. If the clinical or image interpretation does not parallel your findings or if I can be of any further assistance please contact me.



DATE

3/24/23 **L.D. McGill, DVM, Ph.D., DACVP**
8288 Top of the World Drive
Cottonwood Heights, UT 84121
ldmcgill.vetpath@gmail.com
cell: 801-865-1220

INTERPRETED BY

L.D. McGill, DVM, Ph.D.,
DACVP

PATIENT

Zoey Behiri

SPECIES

Canine

BREED

Goldendoodle

SEX

Female Spayed

AGE

9y

WEIGHT

61.5

HOSPITAL NAME

Rotterdam Veterinary
Hospital

REFERRING VET

Dr. Scarpinato

INVOICE NUMBER

922