



DATE PRESENTING CLINICAL SIGNS

3/24/22

Low-grade chronic pancreatitis. US showed variable gastrointestinal thickening and enlarged mesenteric lymph nodes. the largest LN encompassed the mesenteric artery. FNA of lymph node performed. R/O lymphoma vs lymphadenitis

INTERPRETED BY CYTOLOGY SUBMISSION

L.D. McGill, DVM,
Ph.D, DACVP

Lymph node

PATIENT

Teddy Whitman

OBSERVATIONS

Lymph node: Submitted are 5 excellent videos of excellent collections of cells from the enlarged mesenteric lymph node in Teddy. The cellularity consists of large numbers of rounded cells, many of which are quite large. There are scattered neutrophils and a few small lymphocytes scattered throughout. More than 60% of the cells are the large irregular cells with nuclei that are 2 to 4 times the size of red blood cells. These nuclei have prominent nucleoli that are somewhat varied. Mitotic figures are readily identified. There are very few plasma cells present.

SPECIES INTERPRETATION OF THE FINDINGS & FURTHER RECOMMENDATIONS

Canine

Lymph node - Consistent with high grade lymphoma.

BREED

West Highland Terrier

COMMENTS

The cellularity is most consistent with a high-grade lymphoma with large numbers of large cells of the lymphoid type with atypical nuclei. There is mild inflammation but it is minimal compared to the large numbers of atypical lymphoid cells. If chemotherapy is contemplated, immunophenotyping of the cells in this collection may be beneficial to identify cell type. This information may contribute to the prognosis. These slides may be submitted for PARR testing or biopsy and immunohistochemistry staining can be undertaken. Re-collection for flow cytometry evaluation will be required if that testing is desired. You may wish to contact the laboratory to confirm the sample required for flow cytometry. Due to the large size of the cells, an unfavorable prognosis is warranted in my opinion. Teddy may respond to chemotherapy.

AGE

7y

WEIGHT

N/A

HOSPITAL NAME

All Creatures Great &
Small Denville

REFERRING VET

Dr. Mitrovic

INVOICE NUMBER

697

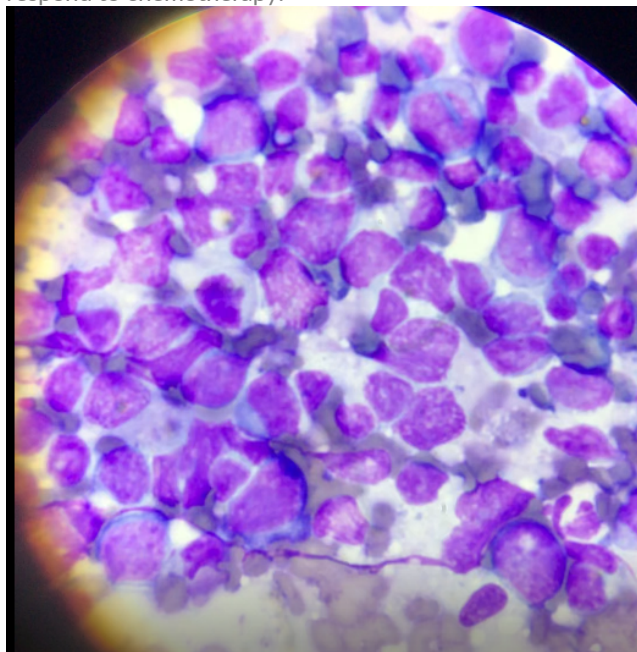


Image shows a field of large numbers of lymphoid cells that have large nuclei collected from Teddy. There is a mitotic figure in the left of center.



DATE

3/24/22

INTERPRETED BY

L.D. McGill, DVM,
Ph.D, DACVP

The information and recommendations provided are based on the images presented by the referring veterinarian. No evaluation can be communicated regarding pathology that was not visible in the image/video clips provided.

Thank you for this referral. If the clinical or image interpretation does not parallel your findings or if I can be of any further assistance please contact me.

PATIENT

Teddy Whitman

L.D. McGill, DVM, Ph.D., DACVP

8288 Top of the World Drive
Cottonwood Heights, UT 84121

SPECIES

ldmcgill.vetpath@gmail.com
cell: 801-865-1220

Canine

BREED

West Highland Terrier

SEX

Male Neutered

AGE

7y

WEIGHT

N/A

HOSPITAL NAME

All Creatures Great &
Small Denville

REFERRING VET

Dr. Mitrovic

INVOICE NUMBER

697