



DATE PRESENTING CLINICAL SIGNS

3/24/22

The cat was in the boarding and started coughing and sneezing. The cat is not vaccinated. X-Ray showed prominent bronchial pattern. BAL was done and the cyto sample from the fluid has been submitted. Last month dorsal laminectomy was done for this cat. Coughing and sneezing

INTERPRETED BY CYTOLOGY SUBMISSION

L.D. McGill, DVM,
Ph.D, DACVP

FNA of BAL

OBSERVATIONS

BAL: Submitted are several images of minimal numbers of cells collected from the BAL smears from Pale. The cellularity is minimal in these images. The most numerous cellularity includes neutrophils with scattered eosinophils. There are scattered macrophages and rare lymphocytes. Specific etiologic agents are not identified.

PATIENT

Pale Mariam

INTERPRETATION OF THE FINDINGS & FURTHER RECOMMENDATIONS

BAL - Mild chronic suppurative and eosinophilic bronchitis.

SPECIES

Feline

COMMENTS

The cellularity in this collection supports an inflammatory process with some suggestion of allergy with the eosinophils that are included. This is likely an allergic reaction with secondary bacterial infection. Treatment with antibiotics and anti-inflammatories may be beneficial. Heartworm infestation can be considered. Parasites might stimulate an eosinophilic response. Due to the minimal numbers of cells, I cannot suggest any other type of response.

BREED

Domestic Shorthair

SEX

Male

AGE

2years

WEIGHT

4.3kg

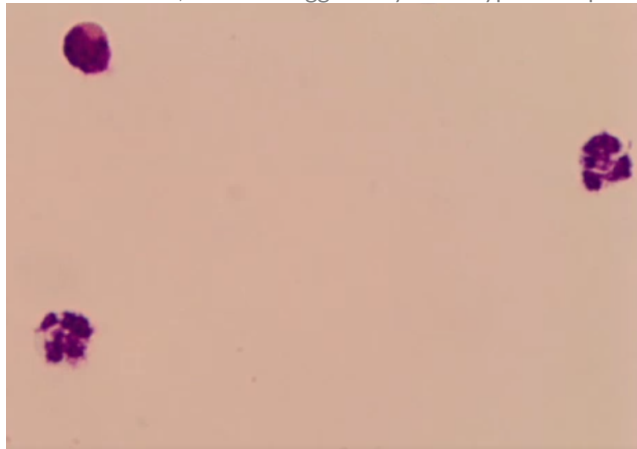


Image shows 2 neutrophils and an eosinophil in the upper left corner. The neutrophils appear degenerate which could be due to sitting on the fluid or a bacterial infection.

HOSPITAL NAME

City Veterinary Clinic
Alain

The information and recommendations provided are based on the images presented by the referring veterinarian. No evaluation can be communicated regarding pathology that was not visible in the image/video clips provided.

Thank you for this referral. If the clinical or image interpretation does not parallel your findings or if I can be of any further assistance, please contact me.

REFERRING VET

Dr. Inam ul haq

L.D. McGill, DVM, Ph.D., DACVP
8288 Top of the World Drive
Cottonwood Heights, UT 84121
ldmcgill.vetpath@gmail.com
cell: 801-865-1220

INVOICE NUMBER

40487



DATE

3/24/22

INTERPRETED BY

L.D. McGill, DVM,
Ph.D, DACVP

PATIENT

Pale Mariam

SPECIES

Feline

BREED

Domestic Shorthair

SEX

Male

AGE

2years

WEIGHT

4.3kg

HOSPITAL NAME

City Veterinary Clinic
Alain

REFERRING VET

Dr. Inam ul haq

INVOICE NUMBER

40487