



DATE PRESENTING CLINICAL SIGNS

3/24/22

During a physical exam on 3/23/22 a firm subcutaneous mass of ~15mm was found in the left flank area. Owner had not noted the mass before. No abnormalities on BW 3/23/22

INTERPRETED BY CYTOLOGY SUBMISSION

L.D. McGill, DVM,
Ph.D, DACVP

FNA of Left flank mas

PATIENT

Karma Keyes

OBSERVATIONS

Left flank mass: Submitted are 3 excellent videos of cells collected from the left flank mass on Karma. The cellularity consists of large numbers of round cells many of which contain large numbers of purple to metachromatic granules. Some of the cells are only partially granulated. Associated with these granulated cells are large numbers of eosinophils. A very few neutrophils and lymphocytes are identified. The cells with irregular metachromatic granules are mast cells. Some are well granulated.

INTERPRETATION OF THE FINDINGS & FURTHER RECOMMENDATIONS

SPECIES Left flank mass - Mast cell tumor suggestive of intermediate to high grade.

Canine

COMMENTS

The cellularity is definitely that of a mast cell tumor with secondary severe eosinophilic inflammation. There appears to be extensive fluid and edema. This growth could be a grade 2 or grade 3 mast cell tumor. The cells are not as well granulated as I would expect for low-grade. Wide excision of the mass is encouraged. I cannot grade the mass cytologically but excision of the mass with a follow-up biopsy to determine margins and grade would be encouraged. A guarded prognosis is warranted with mast cell tumors in the dermis or subcutaneous tissue in the dog.

BREED

Golden Retriever

SEX

FS

AGE

14y

WEIGHT

67.6#

HOSPITAL NAME

Rotterdam Veterinary
Hospital

REFERRING VET

Dr. Anna St Sir

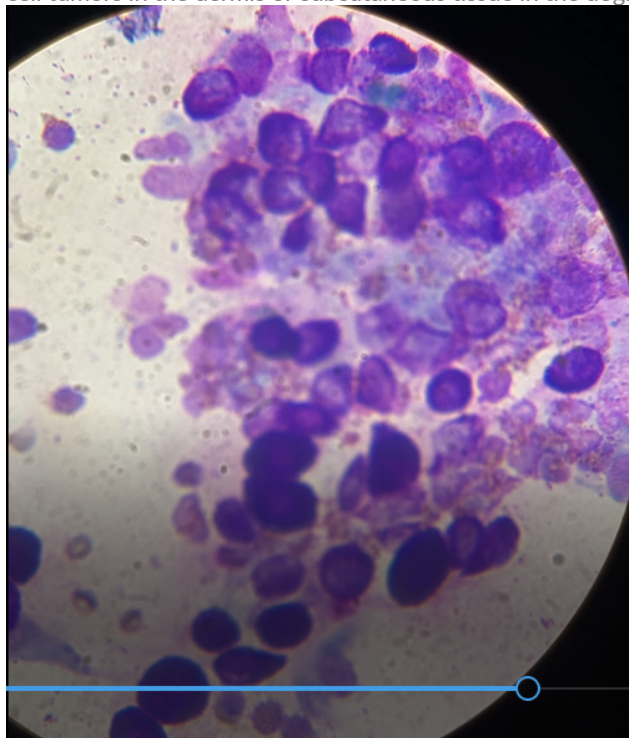


Image shows a group of mast cells with irregular granularity collected from Karma. Large numbers of eosinophils are also associated with these cells.

INVOICE NUMBER

40488



DATE 3/24/22 The information and recommendations provided are based on the images presented by the referring veterinarian. No evaluation can be communicated regarding pathology that was not visible in the image/video clips provided.

INTERPRETED BY Thank you for this referral. If the clinical or image interpretation does not parallel your findings or if I can be of any further assistance, please contact me.

L.D. McGill, DVM, Ph.D., DACVP
L.D. McGill, DVM, Ph.D., DACVP
8288 Top of the World Drive
Cottonwood Heights, UT 84121
ldmcgill.vetpath@gmail.com
cell: 801-865-1220

PATIENT

Karma Keyes

SPECIES

Canine

BREED

Golden Retriever

SEX

FS

AGE

14y

WEIGHT

67.6#

HOSPITAL NAME

Rotterdam Veterinary Hospital

REFERRING VET

Dr. Anna St Sir

INVOICE NUMBER

40488