



DATE PRESENTING CLINICAL SIGNS

3/23/22

Unknown cause of inappetence, vomiting, loose stool and abdominal discomfort. Current meds: Metronidazole liq.125mg/ml 1ml bid, Convenia inj. Famotidine sid.

ULTRASONOGRAPHIC FINDINGS

- Segmental to generalized infiltrative enteropathy with potential for early segmental mural masses and inefficient peristalsis pattern.
 - Associated hypoechoic to prominent jejunocolic lymphadenopathy.
 - Regional peri intestinal to perilymphatic reactive mesentery and scant free fluid.
- Abnormal PE/Chem/CBC/UA Results: WBC 23.28, NEU 19.02, MONO 0.69, GLOB 5.4

INTERPRETED BY

L.D. McGill, DVM,
Ph.D, DACVP

PATIENT CYTOLOGY SUBMISSION

Woody Galate

FNA of Lymph Node

OBSERVATIONS

Lymph node: Submitted are 3 excellent videos of the cells collected from the mesenteric lymph node in Woody. The cellularity is mixed. The majority of the cells are small mature lymphocytes throughout all of the smears. There are scattered macrophages and neutrophils. An occasional eosinophils is present. There are a few reactive in large lymphoid cells but they are few in number.

SPECIES

Feline

INTERPRETATION OF THE FINDINGS & FURTHER RECOMMENDATIONS

Mesenteric lymph node - Chronic pyogranulomatous lymphadenitis with mild reactive lymphoid tissue.

BREED

DLH

COMMENTS

The cellularity is mixed supporting chronic inflammation. This inflammation could be the result of feline infectious peritonitis. It could also be the result of chronic inflammation draining from the intestine either as a result of bacterial infection or possibly intestinal lymphoma with secondary inflammation. The cellularity in the lymph node does not support neoplasia. Intestinal lymphoma in the cat and dog may not affect the regional lymph nodes except with inflammation which is present in these videos. Intestinal lymphoma often has specific markers on the tumor cells that will only grow in the intestine. If problems continue and further diagnostics are desired, then aspiration of the wall of the intestine or follow-up intestinal biopsies are encouraged. A guarded to unfavorable prognosis is warranted. These smears can be submitted to the laboratory for PCR testing for feline coronavirus to assist in ruling in FIP or ruling out that disease process.

AGE

11y

WEIGHT

16# 4oz

HOSPITAL NAME

ACC Flanders

REFERRING VET

Dr. Hallihan

INVOICE NUMBER

40486

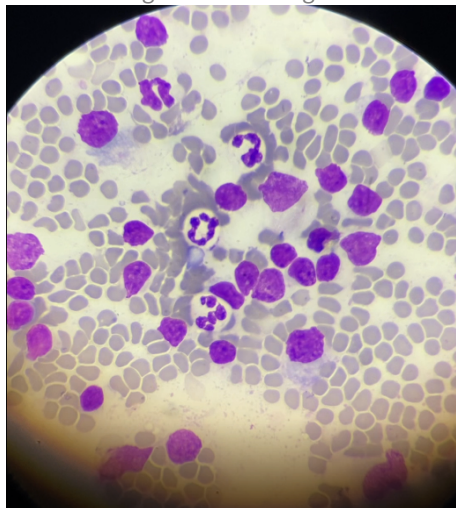


Image shows neutrophils with reactive lymphocytes and many small lymphocytes with a couple of macrophages collected from Woody.



DATE

3/23/22

The information and recommendations provided are based on the images presented by the referring veterinarian. No evaluation can be communicated regarding pathology that was not visible in the image/video clips provided.

INTERPRETED BY

L.D. McGill, DVM,
Ph.D, DACVP

Thank you for this referral. If the clinical or image interpretation does not parallel your findings or if I can be of any further assistance, please contact me.

PATIENT

Woody Galate

L.D. McGill, DVM, Ph.D., DACVP
8288 Top of the World Drive
Cottonwood Heights, UT 84121
ldmcgill.vetpath@gmail.com
cell: 801-865-1220

SPECIES

Feline

BREED

DLH

SEX

Male Neutered

AGE

11y

WEIGHT

16# 4oz

HOSPITAL NAME

ACC Flanders

REFERRING VET

Dr. Hallihan

INVOICE NUMBER

40486