



**DATE PRESENTING CLINICAL SIGNS**

3/22/22

Splenic mass suspected on radiographs, rounded liver

**CYTOLOGY SUBMISSION**

Liver; spleen

**INTERPRETED BY**

L.D. McGill, DVM,  
Ph.D, DACVP

**OBSERVATIONS**

Liver: Submitted are 3 videos of cells collected from the liver in Malibu. The cells consist of scattered hepatocytes and a few small collections of hepatocytes with prominent collections of neutrophils and lymphocytes. The neutrophils are quite prominent in many fields. Degenerate cells are prominent. Malignant characteristics are not identified.

**PATIENT**

Malibu Pamila

Spleen: Submitted are 5 videos of excellent collections of cells from the spleen in Malibu. There is a mixture of cellularity which includes neutrophils, lymphocytes and nucleated RBCs. Degenerate debris and protein are identified through the collection. Neutrophils are quite prominent throughout the collection. There is no suggestion of malignancy in this collection.

**SPECIES**

Canine

**INTERPRETATION OF THE FINDINGS & FURTHER RECOMMENDATIONS**

Liver - Chronic suppurative hepatitis with hepatocellular vacuolization and granularity  
Spleen - Chronic suppurative splenitis with extramedullary hematopoiesis.

**COMMENTS**

**BREED**

Pit Mix

The changes in the liver and spleen support chronic inflammation. This inflammation could be the result of problems in other organs including the pancreas or intestine. There could be some type of systemic inflammatory process. There is no suggestion of malignancy in the collection nor can I identify specific etiologic agents. Treatment with anti-inflammatories and antibiotics may be beneficial in this case. If problems continue, then exploratory evaluation of Malibu may be beneficial.

**SEX**

Female Spayed

**AGE**

12y

**WEIGHT**

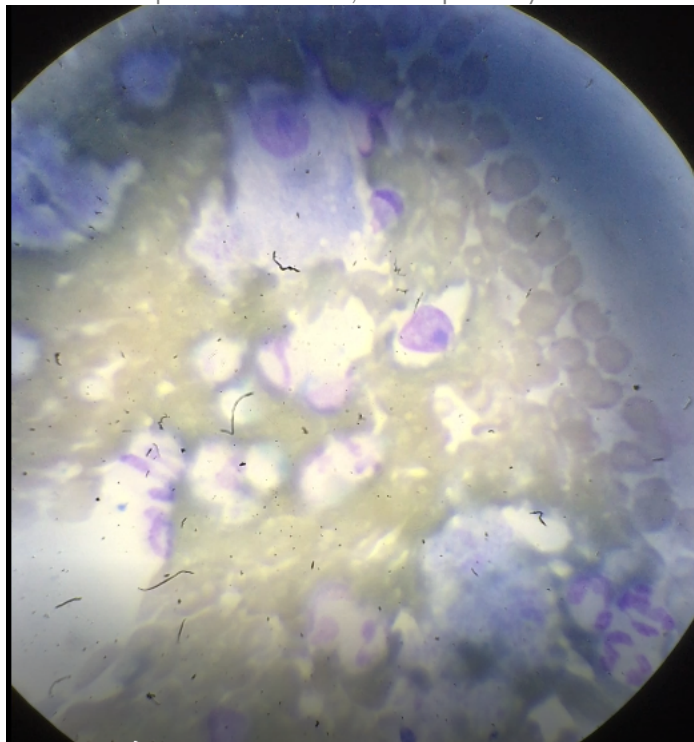
68.1lbs

**HOSPITAL NAME**

Newton Veterinary  
Hospital

**REFERRING VET**

Dr. Wyman-Greenwald



**INVOICE NUMBER**

696

Image shows a lightly stained collection of cells with a hepatocyte and scattered neutrophils and lymphocytes collected from Malibu.



**DATE**

3/22/22

**INTERPRETED BY**

L.D. McGill, DVM,  
Ph.D, DACVP

**PATIENT**

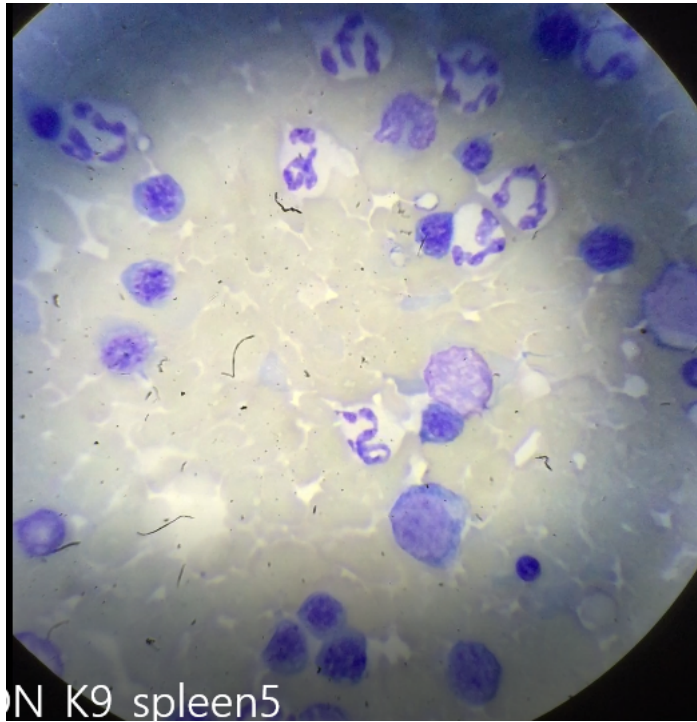
Malibu Pamila

**SPECIES**

Canine

**BREED**

Pit Mix



N K9 spleen5

Image shows a representative group of cells collected from the spleen in Malibu. Note the prominent neutrophils. Nucleated RBCs are overly represented.

**SEX**

Female Spayed

**AGE**

12y

**WEIGHT**

68.1lbs

**HOSPITAL NAME**

Newton Veterinary  
Hospital

**REFERRING VET**

Dr. Wyman-Greenwald

**INVOICE NUMBER**

696

The information and recommendations provided are based on the images presented by the referring veterinarian. No evaluation can be communicated regarding pathology that was not visible in the image/video clips provided.

Thank you for this referral. If the clinical or image interpretation does not parallel your findings or if I can be of any further assistance please contact me.

L.D. McGill, DVM, Ph.D., DACVP  
8288 Top of the World Drive  
Cottonwood Heights, UT 84121  
ldmcgill.vetpath@gmail.com  
cell: 801-865-1220