



DATE PRESENTING CLINICAL SIGNS

3/21/23

Palpable cranial abdominal mass, vomiting, progressive weight loss, and anorexia.
Current med: Pepcid.

INTERPRETED BY

L.D. McGill, DVM, Ph.D,
DACVP

CYTOLOGY SUBMISSION

Abdominal mass

OBSERVATIONS

Abdominal mass: Submitted are 11 videos and images collected from the abdominal mass in Patty. The cells consist of large numbers of round cells. Some of the cells are large lymphoid cells with large nuclei that are 4 to 6 times the size of red blood cells. These cells have prominent irregular nucleoli. There are scattered neutrophils and scattered macrophages. There are a few small to intermediate size lymphocytes.

PATIENT

Patty Molnar

INTERPRETATION OF THE FINDINGS & FURTHER RECOMMENDATIONS

Abdominal mass - Suggestive of high-grade lymphoma.

SPECIES

Feline

COMMENTS

The cellularity strongly suggests the likelihood of a high-grade lymphoma in this mass. There are many large lymphocytes and they have prominent nucleoli. There is some secondary inflammation. Confirmation of this diagnosis is encouraged. This can be undertaken with PARR testing or immunophenotyping of the cells. This is particularly necessary if chemotherapy is contemplated. A guarded to unfavorable prognosis is warranted, in my opinion.

BREED

DSH

SEX

Female Spayed

AGE

2007

WEIGHT

HOSPITAL NAME

Franklin Lakes Animal
Hospital

REFERRING VET

Dr. Zilberman

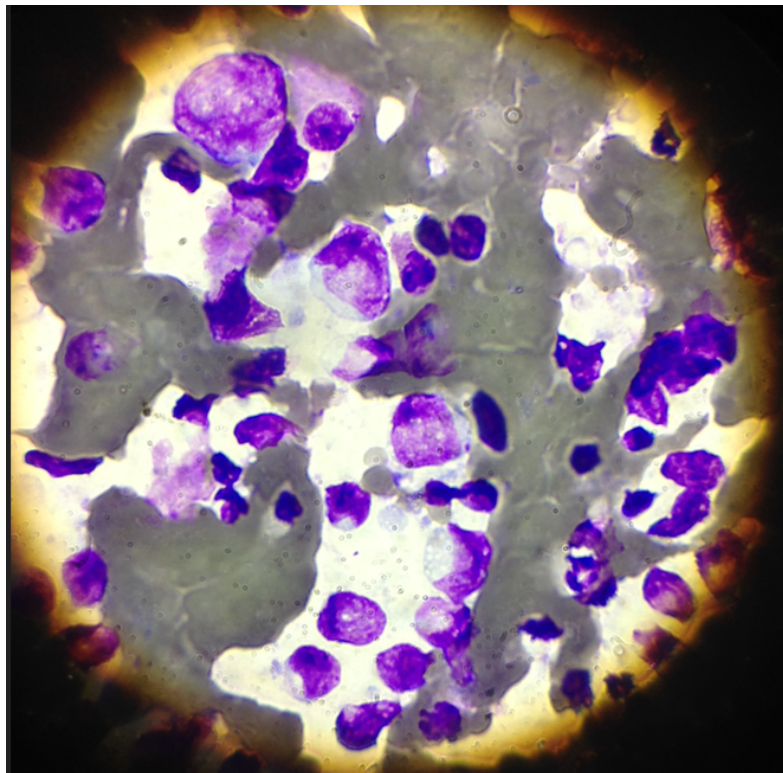


Image shows a good group of lymphocytes, many of which are large with prominent nucleoli collected from the abdominal mass in Patty. There are scattered small mature lymphocytes also.

INVOICE NUMBER

921



DATE

3/21/23

The information and recommendations provided are based on the images presented by the referring veterinarian. No evaluation can be communicated regarding pathology that was not visible in the image/video clips provided.

INTERPRETED BY

L.D. McGill, DVM, Ph.D,
DACVP

Thank you for this referral. If the clinical or image interpretation does not parallel your findings or if I can be of any further assistance please contact me.

L.D. McGill, DVM, Ph.D., DACVP

8288 Top of the World Drive
Cottonwood Heights, UT 84121
ldmcgill.vetpath@gmail.com
cell: 801-865-1220

PATIENT

Patty Molnar

SPECIES

Feline

BREED

DSH

SEX

Female Spayed

AGE

2007

WEIGHT

HOSPITAL NAME

Franklin Lakes Animal
Hospital

REFERRING VET

Dr. Zilberman

INVOICE NUMBER

921