



DATE PRESENTING CLINICAL SIGNS

3/12/22

Seen 6 weeks ago for ADR. Lab work at that time showed mild, non regenerative anemia (HCT 26%); Low/Normal WBC and low PLatelets on IDEXX machine (not confirmed on slide). No Tx was done at that time.

INTERPRETED BY

L.D. McGill, DVM,
Ph.D, DACVP

Seen today for weight loss and ADR; Is eating okay. Has lost 2.25lbs in 6 weeks.
HCT: 17% w/ 0.1% Retics.
WBC Low at 2,700
PLatelets low and confirmed on slide @ 3-4/hpf.
Albumin 2.2
Creat/BUN just at low end.

PATIENT

Five Dee

CYTOLOGY SUBMISSION

FNA of Spleen

OBSERVATIONS

SPECIES

Feline

Spleen: Submitted are 10 excellent videos of moderate to excellent collections of cells from the spleen in Five Dee. The cellularity is mixed with a preponderance of round cells. The round cells have minimal cytoplasm. Where cytoplasm is present, it is bluish gray. Many of the nuclei are quite large and irregular with prominent nucleoli. Scattered mitotic figures are observed. There are scattered macrophages and a few neutrophils in the collection. Many of the round cells have atypical patterns of nuclei.

BREED

DSH

INTERPRETATION OF THE FINDINGS & FURTHER RECOMMENDATIONS

Spleen - Consistent with large cell, high-grade lymphoma.

COMMENTS

Male Neutered

The changes in the cellularity submitted are strongly supportive of a high-grade lymphoma. The cells are quite large and irregular and pleomorphic. There are small lymphoid cells but they are few in number. Macrophages and neutrophils are occurring secondarily. If therapy is contemplated, then immunophenotyping the cells to determine whether T or B cells may be beneficial for prognosis in Five Dee. These smears can be submitted to the laboratory for PARR testing. An unfavorable prognosis is warranted in my opinion.

AGE

12 Years

WEIGHT

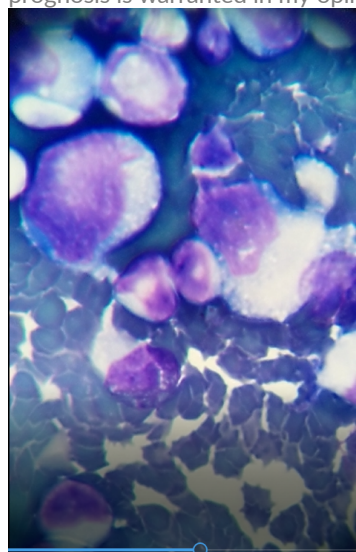
9.25lbs

HOSPITAL NAME

Franklin Animal Clinic
Inc.

REFERRING VET

Dr. Sam Doverspike



INVOICE NUMBER

70470

Image shows some of the large atypical cells collected from the spleen in Five Dee. They are much larger than the neutrophils in the image.



DATE

3/12/22

The information and recommendations provided are based on the images presented by the referring veterinarian. No evaluation can be communicated regarding pathology that was not visible in the image/video clips provided.

INTERPRETED BY

L.D. McGill, DVM,
Ph.D., DACVP

Thank you for this referral. If the clinical or image interpretation does not parallel your findings or if I can be of any further assistance, please contact me.

PATIENT

Five Dee

L.D. McGill, DVM, Ph.D., DACVP
8288 Top of the World Drive
Cottonwood Heights, UT 84121
ldmcgill.vetpath@gmail.com
cell: 801-865-1220

SPECIES

Feline

BREED

DSH

SEX

Male Neutered

AGE

12 Years

WEIGHT

9.25lbs

HOSPITAL NAME

Franklin Animal Clinic
Inc.

REFERRING VET

Dr. Sam Doverspike

INVOICE NUMBER

70470