



DATE PRESENTING CLINICAL SIGNS

3/17/23 Acute onset enlarged lymph nodes, non-painful.
Peripheral lymphadenopathy - obtained samples from R mandibular, L prescapular and R popliteal LN. Remainder of PE is unremarkable. BW not performed at this time.

INTERPRETED BY CYTOLOGY SUBMISSION

L.D. McGill, DVM, Ph.D,
DACVP

Lymph node

OBSERVATIONS

PATIENT

Sky Kiele

Lymph node: Submitted are 2 good videos and 6 good images of cells collected from the lymph nodes in Sky. The cellularity consists almost entirely of round cells which are large lymphocytes. These lymphocytes have minimal cytoplasm. The nuclei are 2 to 6 times the size of red blood cells. Nucleoli are prominent and multiple. There are degenerative debris collections with some macrophages. Lymphoglandular structures are identified.

INTERPRETATION OF THE FINDINGS & FURTHER RECOMMENDATIONS

SPECIES Lymph node - Large numbers of irregular lymphoid cells consistent with high-grade lymphoma.

Canine

COMMENTS

BREED

West Highland Terrier

The cellularity in this collection strongly suggests a high-grade lymphoma. The cells are quite large with irregular nucleoli. If chemotherapy is contemplated, then immunophenotyping of the cells to confirm the specific cell type may be beneficial for prognosis. The slides may be submitted for PARR testing or new slides that are not stained can be submitted for immunocytochemistry staining. Flow cytometry can be beneficial but will require a repeat collection of cells prior to submission to the laboratory. Contacting the laboratory to confirm how to submit flow cytometry samples is encouraged. A guarded to unfavorable prognosis is warranted in my opinion. This is due to the fact that even with response to therapy, eventually there could be a more aggressive form of the lymphoma. If Sky is feeling well at this time, then chemotherapy is certainly a consideration. Continued evaluation of the extent of involvement of other lymph nodes in other tissues is encouraged.

SEX

Male Neutered

AGE

14y

WEIGHT

18.1 lbs

HOSPITAL NAME

Ruidoso Animal Clinic

REFERRING VET

Dr. Botkin

INVOICE NUMBER

915



DATE

3/17/23

INTERPRETED BY

L.D. McGill, DVM, Ph.D,
DACVP

PATIENT

Sky Kiele

SPECIES

Canine

BREED

West Highland Terrier

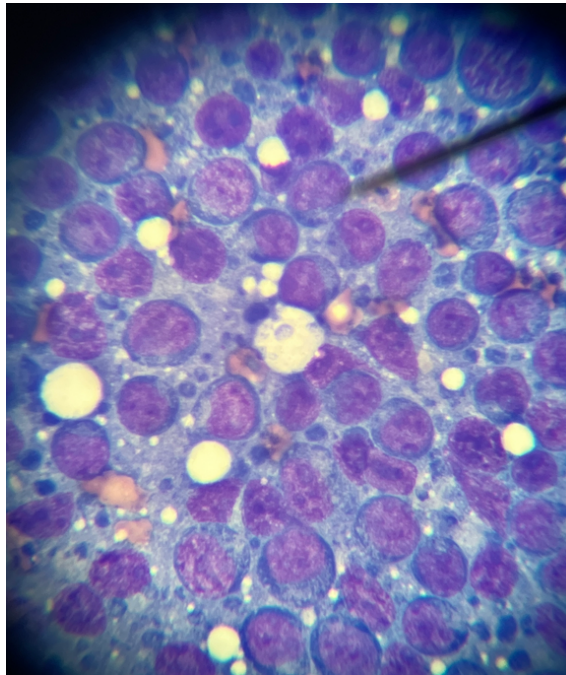


Image shows a representative collection of lymphoid cells from the lymph node in Sky. The bluish granular structures in the background are lymphoglandular bodies.

SEX

Male Neutered

The information and recommendations provided are based on the images presented by the referring veterinarian. No evaluation can be communicated regarding pathology that was not visible in the image/video clips provided.

AGE

14y

Thank you for this referral. If the clinical or image interpretation does not parallel your findings or if I can be of any further assistance please contact me.

WEIGHT

18.1 lbs

L.D. McGill, DVM, Ph.D., DACVP
8288 Top of the World Drive
Cottonwood Heights, UT 84121
ldmcgill.vetpath@gmail.com
cell: 801-865-1220

HOSPITAL NAME

Ruidoso Animal Clinic

REFERRING VET

Dr. Botkin

INVOICE NUMBER

915