



DATE PRESENTING CLINICAL SIGNS

3/17/23 Weight loss, decreased appetite.
Mild elevation in ALP on exam. Ultrasound report pending. Spleen very diffusely hyperechoic.

INTERPRETED BY CYTOLOGY SUBMISSION
Spleen

L.D. McGill, DVM, Ph.D,
DACVP

OBSERVATIONS

Spleen: Submitted are 9 excellent videos of cells collected from the spleen in Luna. The cellularity is mixed with a background of red blood cells. There are neutrophils, lymphocytes and good collections of nucleated RBCs. There are some packets of cells that include macrophages, lymphocytes and nucleated RBCs. There are large aggregates of hemosiderin scattered throughout. There is no suggestion of malignancy in the collection.

PATIENT

Luna Finch Bradford

INTERPRETATION OF THE FINDINGS & FURTHER RECOMMENDATIONS

Spleen - Mixed cell collection with evidence of hematopoiesis and possible hemolysis and mild inflammation.

SPECIES

Canine

COMMENTS

The cellularity in this collection is not specific. There could be some hemolytic process including autoimmune hemolysis with a regeneration of the red blood cells series. Some of the dense cellular structures suggest the possibility of fibrohistiocytic nodules but these are not specific. Hemolysis appears to be a part of the process and there is a good collection of hemosiderin and iron in the spleen. There is no suggestion of malignancy or sepsis. Continued evaluation for a primary process in other organs is encouraged. This could be the result of pancreatitis, enteritis or even inflammation in the liver. A guarded prognosis is warranted since the underlying process is not included in this collection.

BREED

Standard Poodle

SEX

Female Spayed

AGE

9y

WEIGHT

49.8#

HOSPITAL NAME

Ruidoso Animal Clinic

REFERRING VET

Dr. Favis

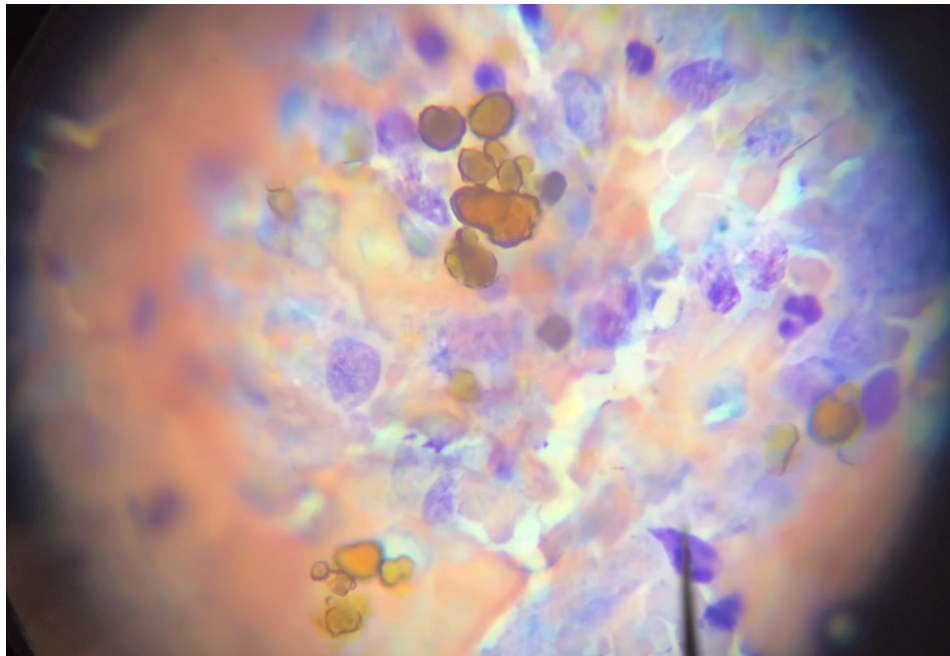


Image demonstrates a group of mixed cells with hemosiderin collected from the spleen in Luna. The hemosiderin is the yellowish-brown granular material.

INVOICE NUMBER

916



DATE 3/17/23 **The information and recommendations provided are based on the images presented by the referring veterinarian. No evaluation can be communicated regarding pathology that was not visible in the image/video clips provided.**

INTERPRETED BY L.D. McGill, DVM, Ph.D., DACVP **Thank you for this referral. If the clinical or image interpretation does not parallel your findings or if I can be of any further assistance please contact me.**

L.D. McGill, DVM, Ph.D., DACVP

L.D. McGill, DVM, Ph.D., DACVP
8288 Top of the World Drive
Cottonwood Heights, UT 84121
ldmcgill.vetpath@gmail.com
cell: 801-865-1220

PATIENT

Luna Finch Bradford

SPECIES

Canine

BREED

Standard Poodle

SEX

Female Spayed

AGE

9y

WEIGHT

49.8#

HOSPITAL NAME

Ruidoso Animal Clinic

REFERRING VET

Dr. Favis

INVOICE NUMBER

916