



DATE PRESENTING CLINICAL SIGNS

3/16/23

Painful abdomen, dehydrated. Had been vomiting profusely, no longer vomiting but not eating. Has not eaten for 4-5 days. Lethargic. FNA of pancreas, the inflamed and walled off area in the body of pancreas.

INTERPRETED BY

L.D. McGill, DVM,
Ph.D, DACVP

BW: CPL abnormal, elevated GGT=20, T bili=0.8, ALB=4.7, TP=7.9, Neutrophilia=39k, Hct=55%, Plt=593.

AUS findings: Regional active potentially necrotic/necrotizing pancreatitis vs suspected pancreatic abscess in the area of the pancreas base with regional peritonitis, minor potential for pancreatic neoplasia possible yet thought less likely.

Pending cytology, aggressive medical therapy vs. surgical exploratory with biopsy and resection of compromised tissue.

PATIENT

Bandit Lizotte

CYTOLOGY SUBMISSION

FNA of Pancreas

SPECIES

Canine

OBSERVATIONS

Pancreas: Submitted are 9 excellent videos of excellent collections of cells from the pancreatic lesion in Bandit. The majority of the cells are neutrophils interspersed with macrophages with foamy cytoplasm. Degenerate debris and lipid are scattered throughout. There is saponified fat in the collection. Neoplastic cells or sepsis are not identified. There are some structures that suggest bacteria in one or two macrophages. They are not massive in numbers.

BREED

Chihuahua

SEX

Male Neutered

INTERPRETATION OF THE FINDINGS & FURTHER RECOMMENDATIONS

Pancreas - Severe pyogranulomatous pancreatitis with necrosis

AGE

6y

COMMENTS

The cellularity is characteristic of an inflammatory process. This suggests a likely bacterial infection and there were a few cells that may contain bacteria. There is no suggestion of malignancy. This type of reaction appears to be due to inflammation. Digestion of fat tissue in this region is likely due to release of pancreatic enzymes. A guarded prognosis is warranted in cases of pancreatitis due to the continued inflammatory reaction. Treatment for severe pancreatitis and antibiotics is encouraged.

WEIGHT

16lbs

HOSPITAL NAME

Scanvet

REFERRING VET

Dr. Bennett

INVOICE NUMBER

40690



DATE

3/16/23

INTERPRETED BY

L.D. McGill, DVM,
Ph.D, DACVP

PATIENT

Bandit Lizotte

SPECIES

Canine

BREED

Chihuahua

SEX

Male Neutered

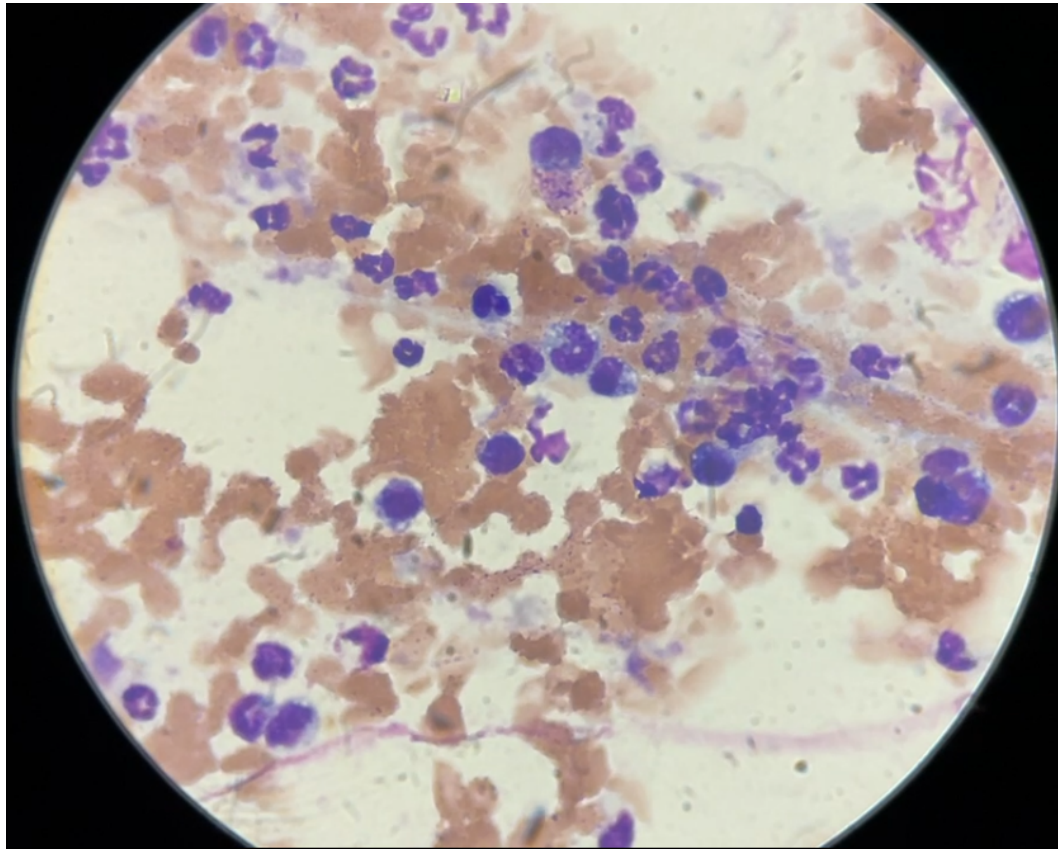


Image shows neutrophils with lymphocytes and a macrophage collected from the pancreas in Bandit. There may be bacterial organisms in the macrophage in the upper center.

AGE

6y

The information and recommendations provided are based on the images presented by the referring veterinarian. No evaluation can be communicated regarding pathology that was not visible in the image/video clips provided.

WEIGHT

16lbs

Thank you for this referral. If the clinical or image interpretation does not parallel your findings or if I can be of any further assistance, please contact me.

HOSPITAL NAME

Scanvet

L.D. McGill, DVM, Ph.D., DACVP
8288 Top of the World Drive
Cottonwood Heights, UT 84121
ldmcgill.vetpath@gmail.com
cell: 801-865-1220

REFERRING VET

Dr. Bennett

INVOICE NUMBER

40690