



DATE PRESENTING CLINICAL SIGNS

3/16/22 Hx of R lump noted under R mandible
Severe periodontal disease (grade IV). Enlarged R mandibular lymph node. no other lymphadenopathy noted at this time. Heart and lungs auscultate WNL. Thin hair coat - suspect endocrinopathy

INTERPRETED BY

L.D. McGill, DVM,
Ph.D, DACVP

CYTOLOGY SUBMISSION

FNA of Submandibular lymph node

PATIENT OBSERVATIONS

Tarra Rakestraw

Submandibular lymph node: Submitted are 9 images of good collections of cells from the submandibular lymph node in Tarra. The cellularity is demonstrating a mixed cellular collection. There are scattered neutrophils and scattered small mature lymphocytes. Macrophages with a foamy granular cytoplasm can be identified. Many of the nuclei are smudged and slightly degenerate. Criteria for malignancy are not identified.

SPECIES

Canine

INTERPRETATION OF THE FINDINGS & FURTHER RECOMMENDATIONS

Submandibular lymph node - Chronic pyogranulomatous lymphadenitis with reactive or stimulated lymph node.

BREED

Yorkshire Terrier

COMMENTS

SEX FS
The cellularity is most consistent with that of a chronic inflammatory process. This is likely draining from the oral problems that you are describing. The changes do not support neoplasia. The lymphoid cells that have large nuclei are due to some degeneration of the nuclear characteristics. No other specific etiologic agents are identified. Treatment for gingivitis and oral inflammation should result in a decrease in the size of this lymph node. A favorable prognosis is likely if Tarra responds to treatment.

AGE

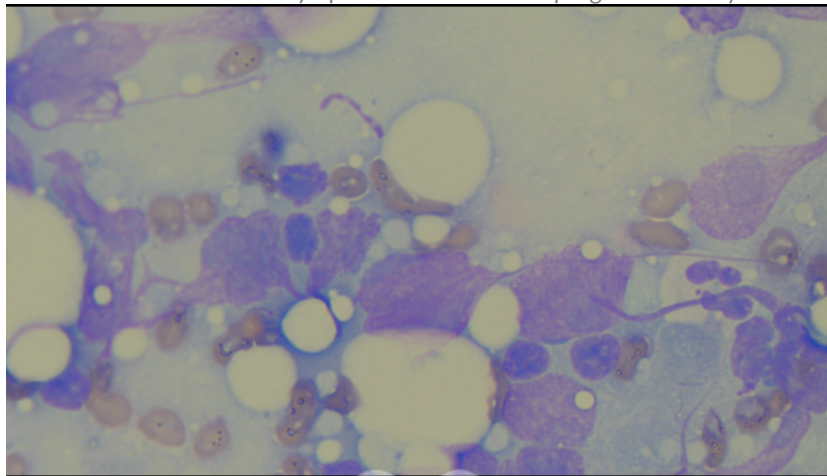
10

WEIGHT

13

HOSPITAL NAME

Torch Lake Veterinary
Clinic



REFERRING VET

Dr. Adrienne Waffle

Image shows lymphocytes and a neutrophil with slightly smudged nuclei collected from Tarra. There appears to be a macrophage present.

INVOICE NUMBER

40482



DATE

3/16/22

The information and recommendations provided are based on the images presented by the referring veterinarian. No evaluation can be communicated regarding pathology that was not visible in the image/video clips provided.

INTERPRETED BY

L.D. McGill, DVM,
Ph.D, DACVP

Thank you for this referral. If the clinical or image interpretation does not parallel your findings or if I can be of any further assistance please contact me.

PATIENT

Tarra Rakestraw

L.D. McGill, DVM, Ph.D., DACVP
8288 Top of the World Drive
Cottonwood Heights, UT 84121
ldmcgill.vetpath@gmail.com
cell: 801-865-1220

SPECIES

Canine

BREED

Yorkshire Terrier

SEX

FS

AGE

10

WEIGHT

13

HOSPITAL NAME

Torch Lake Veterinary
Clinic

REFERRING VET

Dr. Adrienne Waffle

INVOICE NUMBER

40482