



DATE PRESENTING CLINICAL SIGNS

3/16/22

Male intact shepherd with a 6-8 cm alopecic lobulated mass at level of ischial arch just to L of midline (base is thin, but not stalk-like). History of hematuria, so some concern of invasion into perineal urethra

INTERPRETED BY CYTOLOGY SUBMISSION

L.D. McGill, DVM,
Ph.D, DACVP

FNA of Subcutaneous mass

PATIENT

Rugger Legrandeur

OBSERVATIONS

Subcutaneous mass: Submitted are 14 excellent videos of consistent aggregates of cells collected from Rugger. The uniform cellularity consists of elongated to slightly polyhedral cells with elongated nuclei. The nuclei have irregular nucleoli present. The cellularity is rather consistent throughout all of the images. There are scattered neutrophils throughout the collection.

INTERPRETATION OF THE FINDINGS & FURTHER RECOMMENDATIONS

Subcutaneous mass - Soft tissue sarcoma suggestive of fibrosarcoma.

SPECIES

Canine

COMMENTS

The cellularity in this collection is rather consistent through all the images. The nuclei are elongated, and the cytoplasm appears to be elongated to polyhedral. These appearances support spindle cell tumor such as soft tissue sarcoma and particularly fibrosarcoma. Wide excision of the mass is encouraged to eliminate the process. The stalk may be the source of the mass instead of invading in that direction. A guarded prognosis is warranted.

BREED

German Shepherd

SEX

Male

AGE

8

WEIGHT

145

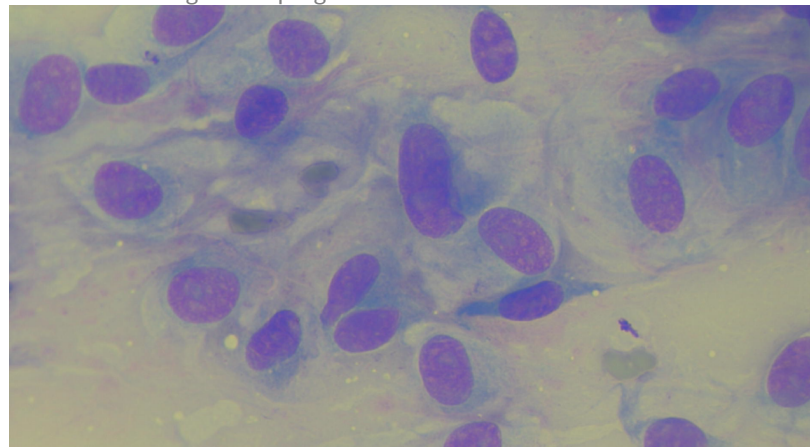


Image shows a representative group of cells collected from Rugger. Note the nuclear variation and prominent nucleoli.

HOSPITAL NAME

Torch Lake Veterinary
Clinic

The information and recommendations provided are based on the images presented by the referring veterinarian. No evaluation can be communicated regarding pathology that was not visible in the image/video clips provided.

Thank you for this referral. If the clinical or image interpretation does not parallel your findings or if I can be of any further assistance, please contact me.

REFERRING VET

Dr. Adrienne Waffle

L.D. McGill, DVM, Ph.D., DACVP

8288 Top of the World Drive
Cottonwood Heights, UT 84121
ldmcgill.vetpath@gmail.com

INVOICE NUMBER

40479

cell: 801-865-1220



DATE

3/16/22

INTERPRETED BY

L.D. McGill, DVM,
Ph.D, DACVP

PATIENT

Rugger Legrandeur

SPECIES

Canine

BREED

German Shepherd

SEX

Male

AGE

8

WEIGHT

145

HOSPITAL NAME

Torch Lake Veterinary
Clinic

REFERRING VET

Dr. Adrienne Waffle

INVOICE NUMBER

40479