



DATE **PRESENTING CLINICAL SIGNS**
3/16/22 Nodular liver, dm, high fever

INTERPRETED BY **CYTOLOGY SUBMISSION**
L.D. McGill, DVM, Ph.D, DACVP FNA of Liver

PATIENT **OBSERVATIONS**
Koko Stang Liver: Submitted are 2 excellent videos of cells collected from the liver in Koko. There are irregular hepatocytes scattered throughout these videos. The hepatocytes demonstrate irregular vacuolization. There is lipid in the background throughout the collection. Some of the hepatocytes are markedly vacuolated. The surrounding red blood cells contain a mixture of inflammatory cells including neutrophils and lymphocytes. There are no changes supporting neoplasia.

SPECIES **INTERPRETATION OF THE FINDINGS & FURTHER RECOMMENDATIONS**
Canine Liver - Marked hepatocellular vacuolization consistent with hepatocellular lipidosis with mild inflammation.

BREED **COMMENTS**
Gret The changes in this liver support severe lipidosis and metabolic liver changes. This can occur secondary to endocrine abnormalities but more commonly will occur secondarily to inflammatory changes in the pancreas or possibly the intestine. There is no suggestion of malignancy or sepsis. The changes support the likelihood of the hepatocytes responding secondarily to problems in other organs in the abdominal cavity including the pancreas, intestine, or possibly adrenal gland. A guarded prognosis is warranted. The specific cause has not been identified at this time. If this were a cat, reestablishing alimentation would be in order.

SEX

Fs

AGE

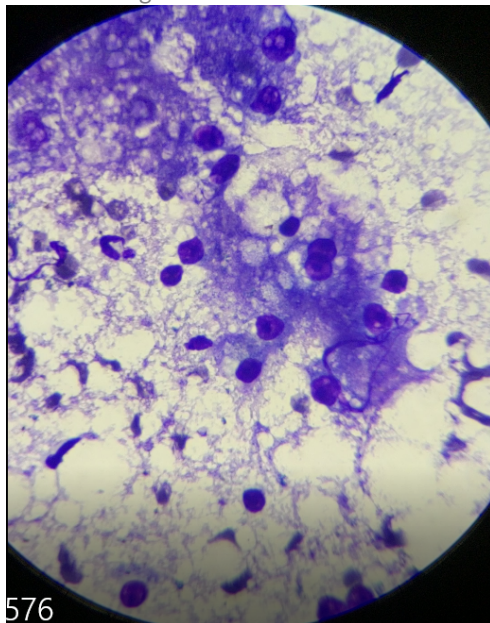
10

WEIGHT

65

HOSPITAL NAME

Bayshore Veterinary Hospital



REFERRING VET Image shows the marked vacuolization of the hepatocytes collected from Koko. There is mild secondary inflammation.

Dr. Hunt

INVOICE NUMBER

40780



DATE 3/16/22 The information and recommendations provided are based on the images presented by the referring veterinarian. No evaluation can be communicated regarding pathology that was not visible in the image/video clips provided.

INTERPRETED BY L.D. McGill, DVM, Ph.D., DACVP Thank you for this referral. If the clinical or image interpretation does not parallel your findings or if I can be of any further assistance please contact me.

L.D. McGill, DVM,
Ph.D., DACVP

L.D. McGill, DVM, Ph.D., DACVP
8288 Top of the World Drive
Cottonwood Heights, UT 84121
ldmcgill.vetpath@gmail.com
cell: 801-865-1220

PATIENT

Koko Stang

SPECIES

Canine

BREED

Gret

SEX

Fs

AGE

10

WEIGHT

65

HOSPITAL NAME

Bayshore Veterinary
Hospital

REFERRING VET

Dr. Hunt

INVOICE NUMBER

40780