



DATE PRESENTING CLINICAL SIGNS

3/15/22

Acute onset ADR, not eating much, lethargy. Weight loss. Intermittent fever (up to 103) over the weekend. Intermittent heart murmur.

PE: Quiet, decreased CP in rear legs.

INTERPRETED BY

L.D. McGill, DVM,
Ph.D, DACVP

AUS: folded spleen with surrounding fluid and micronodular changes, and mild peritoneal free fluid. Concern for round cell neoplasia or possible splenic torsion. Carcinomatosis, lymphomatosis, and similar possible.

BW (3/11) WBC 10.2k w/suspected Bands. ALP 456, Chol 389. CPL: negative

PATIENT CYTOLOGY SUBMISSION

FNA of Abdominal fluid

Boulder LaFore

OBSERVATIONS

SPECIES

Canine

Abdominal fluid: Submitted are 10 excellent videos of excellent collections of cells from the abdominal fluid in Boulder. The fluid has been concentrated resulting in massive numbers of neutrophils. Many of the neutrophils are degenerate and others are not. Some of the neutrophils and macrophages contain structures consistent with bacteria. The aggregates of cells are reactive mesothelial cells. Macrophages are scattered throughout phagocytosing fluid and red blood cells. There are no malignant characteristics in the cells submitted.

BREED

Leonberger

INTERPRETATION OF THE FINDINGS & FURTHER RECOMMENDATIONS

Abdominal fluid - Severe suppurative peritonitis with bacterial infection.

SEX

Male Neutered

COMMENTS

The cellularity is a characteristic severe suppurative inflammatory response. There are structures that suggest bacteria in cells. This supports a bacterial inflammatory process which could be leaking from any organ in the abdominal cavity. This could be from the pancreas or from the intestine. There are no suggestions of neoplasia in the collection but there is definitely change supporting a bacterial infection. Hopefully you considered a culture of the fluid after making the smears. A guarded prognosis is warranted with this severe inflammatory chronic process.

AGE

8 years

WEIGHT

143 lb

HOSPITAL NAME

Scanvet

REFERRING VET

Dr. Berdahl

INVOICE NUMBER

40747



DATE

3/15/22

INTERPRETED BY

L.D. McGill, DVM,
Ph.D, DACVP

PATIENT

Baulder LaFore

SPECIES

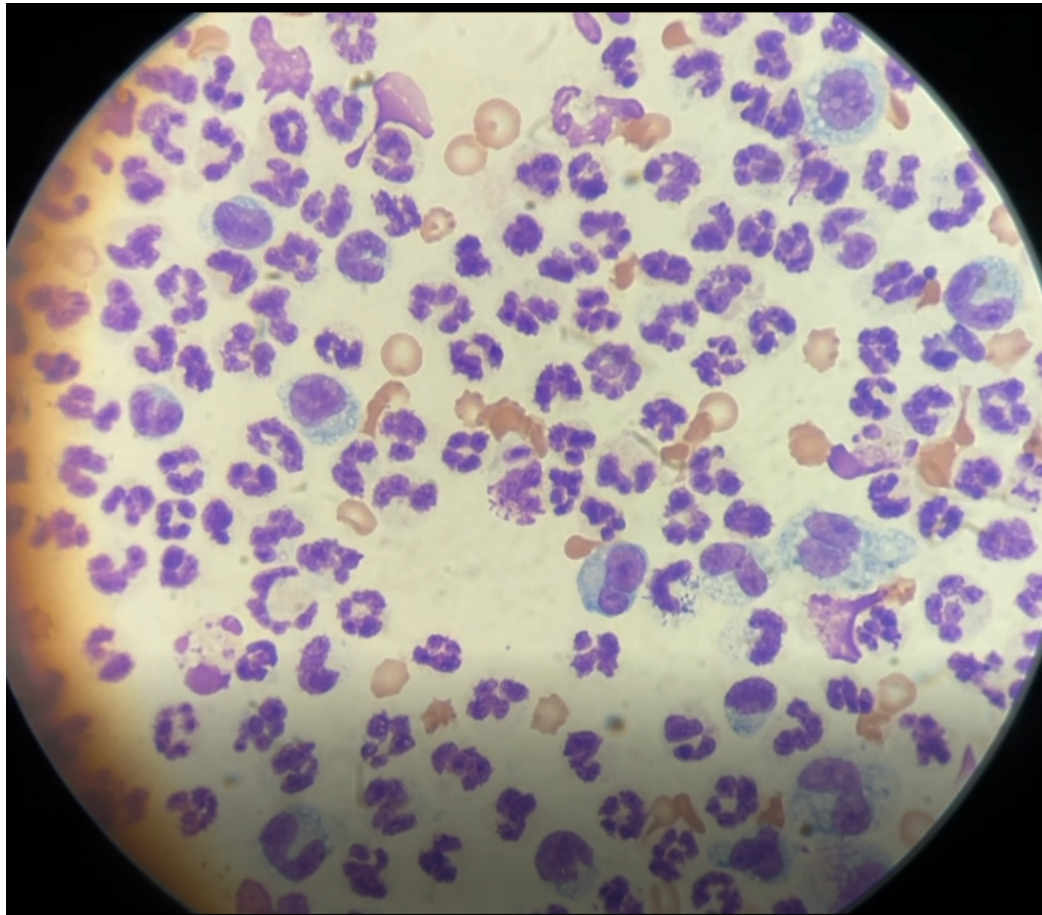
Canine

BREED

Leonberger

SEX

Male Neutered



AGE

8 years

Image shows massive numbers of neutrophils with macrophages from the abdominal cavity in Baulder. Bacteria are present in neutrophils in a cell in the center and center right.

WEIGHT

143 lb

The information and recommendations provided are based on the images presented by the referring veterinarian. No evaluation can be communicated regarding pathology that was not visible in the image/video clips provided.

Thank you for this referral. If the clinical or image interpretation does not parallel your findings or if I can be of any further assistance, please contact me.

HOSPITAL NAME

Scanvet

L.D. McGill, DVM, Ph.D., DACVP
8288 Top of the World Drive
Cottonwood Heights, UT 84121
ldmcgill.vetpath@gmail.com
cell: 801-865-1220

REFERRING VET

Dr. Berdahl

INVOICE NUMBER

40747