



DATE PRESENTING CLINICAL SIGNS

3/15/22 Lymphadenopathy
Lymph 17k, wbc 36. Mesenteric lymphadenopathy as well

INTERPRETED BY CYTOLOGY SUBMISSION

L.D. McGill, DVM,
Ph.D, DACVP
FNA of Lymph node

OBSERVATIONS

PATIENT

Aries Lindquist
Lymph node: Submitted are 2 excellent videos of modern collections of cells from the lymph node in Aries. The cellularity consists of large numbers of lymphoid cells many of which are small to slightly intermediate. There are larger lymphoid cells scattered throughout. There are scattered neutrophils in the collection. Scattered plasma cells are also visualized. The cellularity is not on the aggressive side.

SPECIES INTERPRETATION OF THE FINDINGS & FURTHER RECOMMENDATIONS

Canine
Lymph node - Markedly reactive or stimulated lymph node with mild suppurative inflammation.

BREED COMMENTS

pit
The cellularity in this collection from the lymph node is more characteristic of a reactive or stimulated lymph node than of lymphoma. The clinical history with the high circulating lymphocytes strongly supports lymphoid leukemia. This may suggest that there is lymphoma in the spleen, liver, and bone marrow. This lymph node does not appear to be involved at this time. If it is involved, then it is very early. These smears may be sent to the laboratory for PARR testing to rule out the possibility of lymphoma. A better thought would be to send blood smears with a high lymphocyte count in circulation. A guarded to unfavorable prognosis is warranted due to the high lymphocyte count in circulation.

AGE

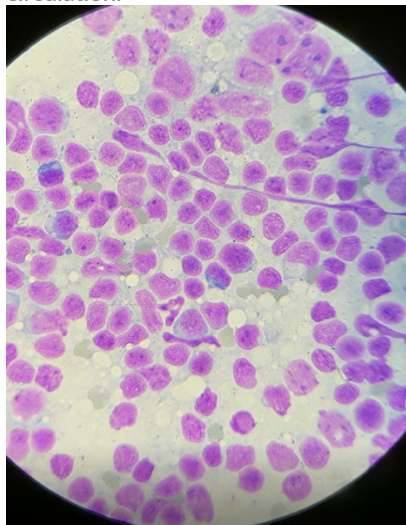
10y

WEIGHT

65

HOSPITAL NAME

Bayshore Veterinary
Hospital



REFERRING VET

Dr. Hunt

Image shows a field of lymphocytes collected from Aries. Most of the nuclei are in the size range of RBCs.

The information and recommendations provided are based on the images presented by the referring veterinarian. No evaluation can be communicated regarding pathology that was not visible in the image/video clips provided.

INVOICE NUMBER

70478



DATE

3/15/22

Thank you for this referral. If the clinical or image interpretation does not parallel your findings or if I can be of any further assistance, please contact me.

INTERPRETED BY

L.D. McGill, DVM,
Ph.D, DACVP

L.D. McGill, DVM, Ph.D., DACVP
8288 Top of the World Drive
Cottonwood Heights, UT 84121
ldmcgill.vetpath@gmail.com
cell: 801-865-1220

PATIENT

Aries Lindquist

SPECIES

Canine

BREED

pit

SEX

Male Neutered

AGE

10y

WEIGHT

65

HOSPITAL NAME

Bayshore Veterinary
Hospital

REFERRING VET

Dr. Hunt

INVOICE NUMBER

70478