



DATE PRESENTING CLINICAL SIGNS

3/13/23

Liver lobectomy last June, Histopath: hepatocellular carcinoma. Recently ADR, lethargic and uncomfortable.

Firm swelling on ventral midline, under previous laparotomy incision, apx. 10 "x 10". US of area shows walled off, irregular, inflamed and painful cystic area. Drained 40mL thick, red, purulent appearing material. +++ remaining in the cystic area.

AUS: GB polypoid changes/mineralized debris, rest of abdomen NSF.

INTERPRETED BY

L.D. McGill, DVM,
Ph.D, DACVP

PATIENT CYTOLOGY SUBMISSION

FNA of Subcutaneous collection

Tuukki Nappi

OBSERVATIONS

SPECIES

Subcutaneous collection: Submitted are 6 excellent videos of cells collected from the subcutaneous fluid on Tuukki. The cellularity is severely degenerate throughout the collection. Many of these degenerate cells are neutrophils. There is no suggestion of malignancy. I was unable to identify bacteria but I suspect that bacteria are prominent. There certainly is no suggestion of malignancy. Inflammation is the major process.

Canine

BREED

Rottweiler

INTERPRETATION OF THE FINDINGS & FURTHER RECOMMENDATIONS

Subcutaneous collection - Severe suppurative and necrotizing collection with probable bacterial infection.

SEX

Male Neutered

COMMENTS

The cellularity in this collection is a characteristic degenerative neutrophilic process. I strongly suspect bacterial infection and I think you said that it was going to be cultured. Culture is important with this type of process. There is no suggestion of malignancy. There is a definite suggestion of inflammation and probable bacterial infection. A guarded prognosis is warranted due to the severe reaction in the potential it has for involving other organs.

AGE

9 years

WEIGHT

150 lbs

HOSPITAL NAME

Scanvet

REFERRING VET

Dr. Peyser

INVOICE NUMBER

40687



DATE

3/13/23

INTERPRETED BY

L.D. McGill, DVM,
Ph.D, DACVP

PATIENT

Tuukki Nappi

SPECIES

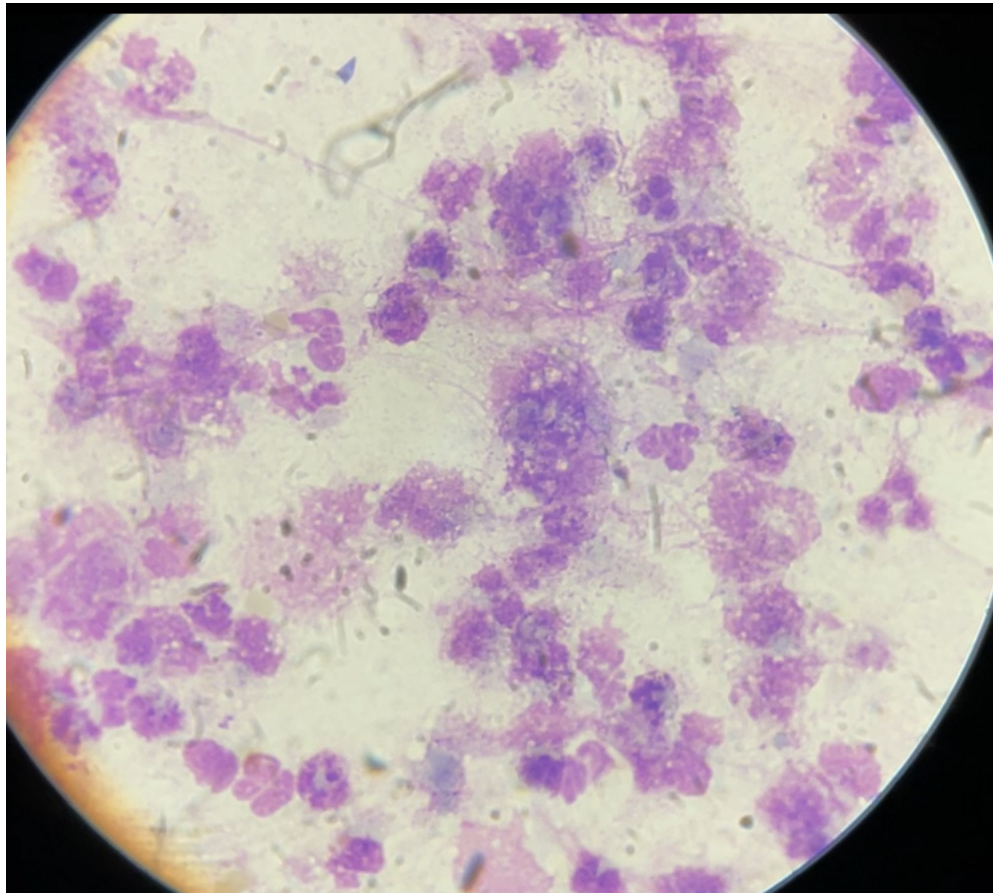
Canine

BREED

Rottweiler

SEX

Male Neutered



AGE

9 years

WEIGHT

150 lbs

Image shows degenerate neutrophils and necrotic cells. There may be bacteria present but hard to see.

The information and recommendations provided are based on the images presented by the referring veterinarian. No evaluation can be communicated regarding pathology that was not visible in the image/video clips provided.

Thank you for this referral. If the clinical or image interpretation does not parallel your findings or if I can be of any further assistance, please contact me.

HOSPITAL NAME

Scanvet

L.D. McGill, DVM, Ph.D., DACVP
8288 Top of the World Drive
Cottonwood Heights, UT 84121
ldmcgill.vetpath@gmail.com
cell: 801-865-1220

REFERRING VET

Dr. Peyser

INVOICE NUMBER

40687