



**DATE PRESENTING CLINICAL SIGNS**

3/10/23 Irregular very firm SQ mass about 2 x 3 cm on thorax/side  
Pancreatitis

**INTERPRETED BY CYTOLOGY SUBMISSION**

Subcutaneous mass

L.D. McGill, DVM, Ph.D,  
DACVP

**OBSERVATIONS**

Subcutaneous mass: Submitted are a large number of excellent images of cells collected from the subcutaneous mass on Milo. The cellularity consists of large numbers of lymphocytes that are round cells. There are very few neutrophils and scattered plasma cells. The lymphoid cells are rather uniform in size and shape. They are small to intermediate. Atypical lymphoid cells are not identified.

**PATIENT**

Milo Francis

**INTERPRETATION OF THE FINDINGS & FURTHER RECOMMENDATIONS**

Subcutaneous mass - Large numbers of small to intermediate lymphocytes consistent with a lymphoid nodule.

**SPECIES**

Canine

**COMMENTS**

This subcutaneous mass is characteristic of a lymphoid nodule. This could be secondary to some type of insect sting or could be in atypical lymph node location. These cells are not characteristic of malignancy. If large numbers of cells or nodules occur in other locations, then there is a possibility of a small cell or an intermediate cell lymphoma but from what I see I cannot make that diagnosis. If problems continue, then a biopsy of the area may be beneficial. Occasionally an injection site granuloma will be lymphocytic in nature. Continued monitoring of Milo for independent lesions is encouraged.

**BREED**

Cockapoo

**SEX**

Male Neutered

**AGE**

6y

**WEIGHT**

54.5 lb

**HOSPITAL NAME**

Rotterdam Veterinary  
Hospital

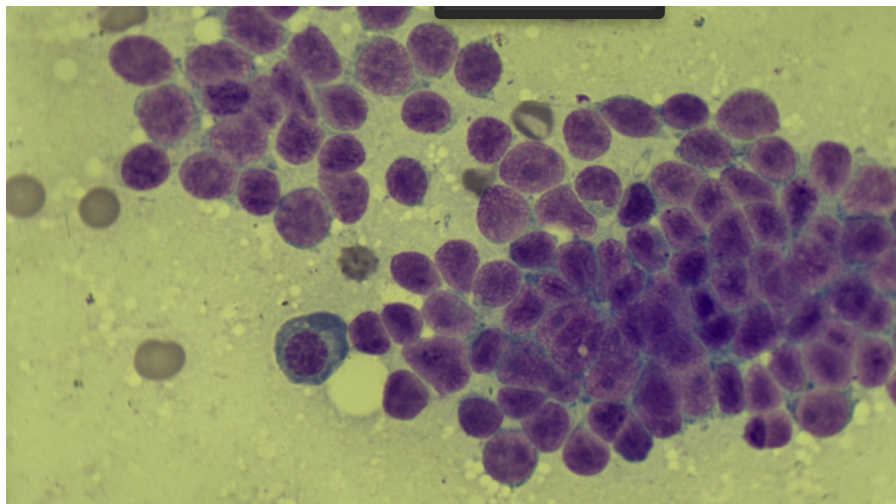


Image shows a group of lymphoid cells collected from the subcutaneous mass on Milo. The darker cell is a plasma cell. Note the lymphocyte nuclei are approximately the size of RBCs.

**REFERRING VET**

Dr. Scarpinato

The information and recommendations provided are based on the images presented by the referring veterinarian. No evaluation can be communicated regarding pathology that was not visible in the image/video clips provided.

Thank you for this referral. If the clinical or image interpretation does not parallel your findings or if I can be of any further assistance please contact me.

**INVOICE NUMBER**

912



**DATE**

3/10/23 **L.D. McGill, DVM, Ph.D., DACVP**  
8288 Top of the World Drive  
Cottonwood Heights, UT 84121  
ldmcgill.vetpath@gmail.com  
cell: 801-865-1220

**INTERPRETED BY**

L.D. McGill, DVM, Ph.D,  
DACVP

**PATIENT**

Milo Francis

**SPECIES**

Canine

**BREED**

Cockapoo

**SEX**

Male Neutered

**AGE**

6y

**WEIGHT**

54.5 lb

**HOSPITAL NAME**

Rotterdam Veterinary  
Hospital

**REFERRING VET**

Dr. Scarpinato

**INVOICE NUMBER**

912