



**DATE PRESENTING CLINICAL SIGNS**

3/10/22 Here for dental but has been losing weight and ADR  
Liver Enzyme Elevations.  
Mass evident in liver...Pending Sonopath Review.

**INTERPRETED BY CYTOLOGY SUBMISSION**

L.D. McGill, DVM,  
Ph.D, DACVP

Liver

**PATIENT**

Cole Barnes

**OBSERVATIONS**

Liver: Submitted are 10 excellent videos of excellent collections of cells from the liver in Cole. The majority of the cells are hepatocytes that are aggregated in irregular patterns. They are not showing cord-like patterns. There is anisocytosis and anisokaryosis in these cells. Other infiltrating cells are not identified. A mitotic figure was identified.

**INTERPRETATION OF THE FINDINGS & FURTHER RECOMMENDATIONS**

Liver - Hepatocellular proliferation suggestive of hepatocellular carcinoma.

**SPECIES**

Canine

**COMMENTS**

The growth of these hepatocytes is disorganized. The cellularity is variable in size and shape. The nuclei are definitely demonstrating anisokaryosis. A mitotic figure is included in the photo. The cytoplasm is slightly irregular and slightly granular. There is no other suggestion of other cellular infiltration into the tissue. Excision biopsy will be required to confirm the cellularity. Excision of the mass may be beneficial if therapy is contemplated. A guarded prognosis is warranted.

**BREED**

Cocker Spaniel

**SEX**

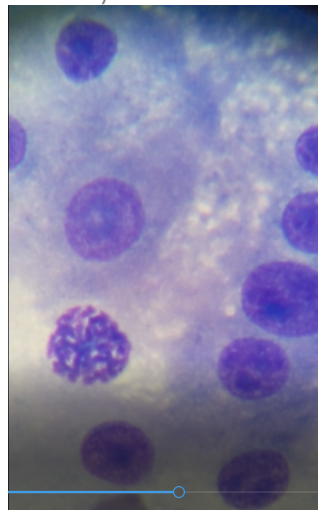
Male

**AGE**

11y

**WEIGHT**

42 lbs



**HOSPITAL NAME**

Franklin Animal Clinic

Image shows representative hepatocytes collected from Cole. Note the anisokaryosis and the early mitotic figure.

**REFERRING VET**

Dr. Doverspike

The information and recommendations provided are based on the images presented by the referring veterinarian. No evaluation can be communicated regarding pathology that was not visible in the image/video clips provided.

Thank you for this referral. If the clinical or image interpretation does not parallel your findings or if I can be of any further assistance please contact me.

**INVOICE NUMBER**

685



**DATE** L.D. McGill, DVM, Ph.D., DACVP

3/10/22  
8288 Top of the World Drive  
Cottonwood Heights, UT 84121  
ldmcgill.vetpath@gmail.com  
cell: 801-865-1220

**INTERPRETED BY**

L.D. McGill, DVM,  
Ph.D., DACVP

**PATIENT**

Cole Barnes

**SPECIES**

Canine

**BREED**

Cocker Spaniel

**SEX**

Male

**AGE**

11y

**WEIGHT**

42 lbs

**HOSPITAL NAME**

Franklin Animal Clinic

**REFERRING VET**

Dr. Doverspike

**INVOICE NUMBER**

685