



DATE **PRESENTING CLINICAL SIGNS**
3/1/22 FNA of liver
ALT 234, ALP 324, Tbili 4.1

INTERPRETED BY **CYTOLOGY SUBMISSION**
Liver

L.D. McGill, DVM,
Ph.D, DACVP

OBSERVATIONS

Liver: Submitted are 6 excellent videos of very good collections of hepatocytes from the liver in Jamari. Almost all of the hepatocytes demonstrate irregular vacuolization. This vacuolization is characteristic of lipid. It is prominent throughout all of the fields in the videos. There are few inflammatory cells in the surrounding RBCs. There are no characteristics of malignancy or sepsis.

PATIENT

Jamari Sorenson

INTERPRETATION OF THE FINDINGS & FURTHER RECOMMENDATIONS

Liver - Severe hepatic lipidosis consistent with feline fatty liver syndrome

SPECIES

Feline

COMMENTS

The changes in the hepatocytic collection strongly support feline fatty liver syndrome. There is no suggestion of malignancy or sepsis. Feline fatty liver syndrome is common in cases of pancreatitis or enteritis. Reestablishing alimentation can be beneficial in some cats. A guarded prognosis is always warranted until we find the underlying cause.

BREED

DSH

SEX

Female Spayed

AGE

9y

WEIGHT

8.8 lbs

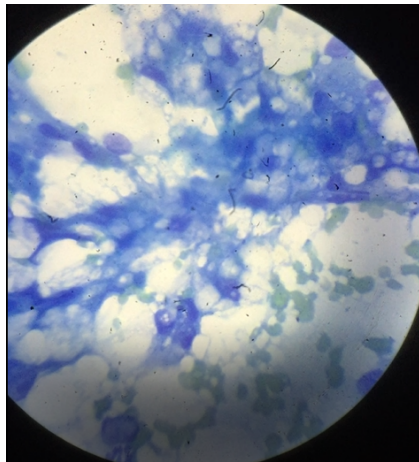


Image shows a representative collection of hepatocytes with lipidosis collected from Jamari. Note the large irregular vacuoles.

HOSPITAL NAME

Newton Veterinary
Hospital

The information and recommendations provided are based on the images presented by the referring veterinarian. No evaluation can be communicated regarding pathology that was not visible in the image/video clips provided.

Thank you for this referral. If the clinical or image interpretation does not parallel your findings or if I can be of any further assistance please contact me.

REFERRING VET

Not provided

L.D. McGill, DVM, Ph.D., DACVP

8288 Top of the World Drive
Cottonwood Heights, UT 84121
ldmcgill.vetpath@gmail.com
cell: 801-865-1220

INVOICE NUMBER

780



DATE

3/1/22

INTERPRETED BY

L.D. McGill, DVM,
Ph.D, DACVP

PATIENT

Jamari Sorenson

SPECIES

Feline

BREED

DSH

SEX

Female Spayed

AGE

9y

WEIGHT

8.8 lbs

HOSPITAL NAME

Newton Veterinary
Hospital

REFERRING VET

Not provided

INVOICE NUMBER

780