



DATE PRESENTING CLINICAL SIGNS

2/9/23

SQ mass found in ventral neck

INTERPRETED BY CYTOLOGY SUBMISSION

L.D. McGill, DVM,
Ph.D, DACVP

FNA of Neck mass

PATIENT

Ava Mahoney

OBSERVATIONS

Neck mass: Submitted are 5 excellent videos of excellent collections of cells from the neck mass on Ava. The cells are all round cells. Most are large lymphoid cells. There are scattered small mature lymphocytes and smudge cells. The larger lymphoid cells have nuclei that are 2-4 times the size of RBCs. Scattered cells have prominent nucleoli. Degenerate cells are prominent. Many of the lymphoid cells are elongated as the result of smearing.

SPECIES

Canine

INTERPRETATION OF THE FINDINGS & FURTHER RECOMMENDATIONS

Neck mass - Consistent with high-grade lymphoma.

BREED

Pitbull

COMMENTS

The cellularity is characteristic of a round cell tumor and high-grade lymphoma appears to be most likely. There are cases of indolent lymphoma that respond to excision of the node particularly in the head or neck region. Excision and further evaluation may be beneficial. These slides can be sent to a laboratory for PARR testing or recollection of cells for flow cytometry can be achieved. A guarded to unfavorable prognosis is warranted in my opinion.

SEX

spayed female

AGE

12y

WEIGHT

61.5 lbs

HOSPITAL NAME

Central Veterinary
Hospital

REFERRING VET

Dr. Michel Hardaker

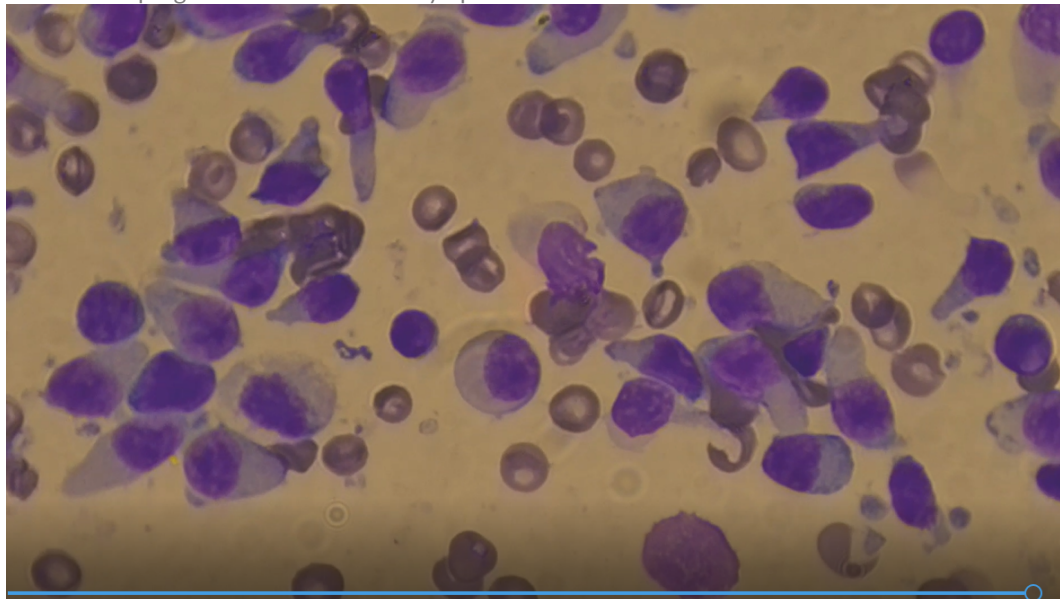


Image shows a representative group of cells collected from the neck lesion on Ava. Note the comparison of most of the cells to the small mature lymphocyte in the center of the image.

INVOICE NUMBER

40655



DATE 2/9/23 The information and recommendations provided are based on the images presented by the referring veterinarian. No evaluation can be communicated regarding pathology that was not visible in the image/video clips provided.

INTERPRETED BY L.D. McGill, DVM, Ph.D., DACVP Thank you for this referral. If the clinical or image interpretation does not parallel your findings or if I can be of any further assistance, please contact me.

L.D. McGill, DVM,
Ph.D., DACVP

L.D. McGill, DVM, Ph.D., DACVP
8288 Top of the World Drive
Cottonwood Heights, UT 84121
ldmcgill.vetpath@gmail.com
cell: 801-865-1220

PATIENT

Ava Mahoney

SPECIES

Canine

BREED

Pitbull

SEX

spayed female

AGE

12y

WEIGHT

61.5 lbs

HOSPITAL NAME

Central Veterinary
Hospital

REFERRING VET

Dr. Michel Hardaker

INVOICE NUMBER

40655