



**DATE PRESENTING CLINICAL SIGNS**

2/9/23 Prostatic enlargement  
Prostate aspiration

**CYTOLOGY SUBMISSION**

**INTERPRETED BY** Prostate

L.D. McGill, DVM,  
Ph.D, DACVP

**OBSERVATIONS**

Prostate: Submitted are 2 excellent videos of moderate to excellent collections of cells from the prostate in Archie. The cellularity consists of packets of epithelial cells demonstrating anisocytosis and anisokaryosis. These cells demonstrate slight vacuolization and granularity. Nuclei demonstrate irregular nucleoli. There are scattered inflammatory cells in the collection. The major cellularity is the collection of epithelial cells.

**PATIENT**

Archie Scramlin

**INTERPRETATION OF THE FINDINGS & FURTHER RECOMMENDATIONS**

Prostate - Consistent with urothelial carcinoma with secondary inflammation.

**SPECIES**

Canine

**COMMENTS**

The cellularity in this collection suggests the likelihood of a urothelial carcinoma derived from the prostatic urethra. This is the most common source for prostatic carcinoma in the dog. This is not the same in man. The epithelial cells have the characteristics of urothelial epithelium. It's possible that this started in the bladder and then has worked its way down into the prostate since you say it is in the bladder also. Consultation with an oncologist may be beneficial, however, an unfavorable prognosis is warranted in my opinion.

**BREED**

Mix

**SEX**

Male Neutered

**AGE**

12

**WEIGHT**

65

**HOSPITAL NAME**

Bayshore Veterinary  
Hospital

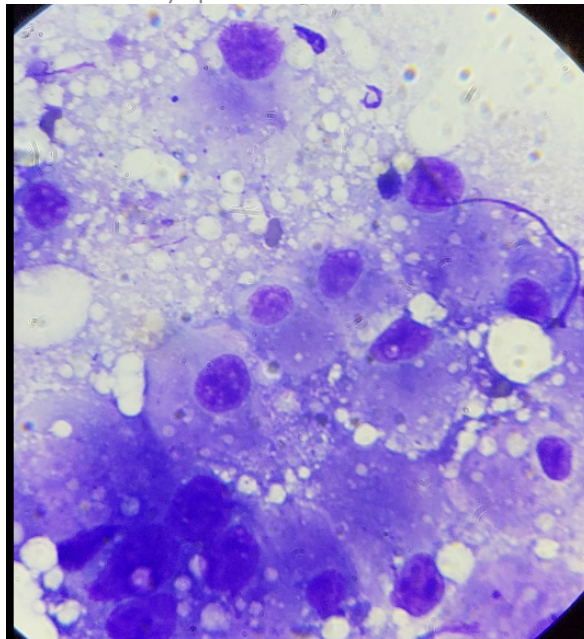


Image demonstrates a group of cells aspirated from the prostate in Archie. Note the anisocytosis and anisokaryosis with vacuolization of the cells suggesting urothelium.

**REFERRING VET**

Dr. Hunt

The information and recommendations provided are based on the images presented by the referring veterinarian. No evaluation can be communicated regarding pathology that was not visible in the image/video clips provided.

**INVOICE NUMBER**

889



**DATE** Thank you for this referral. If the clinical or image interpretation does not parallel your findings or if I can be of any further assistance please contact me.

2/9/23

**INTERPRETED BY** L.D. McGill, DVM, Ph.D., DACVP  
8288 Top of the World Drive  
Cottonwood Heights, UT 84121  
ldmcgill.vetpath@gmail.com  
cell: 801-865-1220

L.D. McGill, DVM,  
Ph.D, DACVP

**PATIENT**

Archie Scramlin

**SPECIES**

Canine

**BREED**

Mix

**SEX**

Male Neutered

**AGE**

12

**WEIGHT**

65

**HOSPITAL NAME**

Bayshore Veterinary  
Hospital

**REFERRING VET**

Dr. Hunt

**INVOICE NUMBER**

889