



DATE PRESENTING CLINICAL SIGNS

2/7/23

Lethargic, Lyme positive, had bronchitis either reverse sneezing or coughing. Decreased appetite.

ULTRASONOGRAPHIC FINDINGS

Minor hypersplenism.
Age related renal, hepatic and pancreatic changes.

INTERPRETED BY

ALT 171, ALKP 377, MCH 26, HGB 20.8, MPV 13.5, urine specific gravity 1.008

L.D. McGill, DVM,
Ph.D, DACVP

CYTOLOGY SUBMISSION

Liver; spleen

OBSERVATIONS

PATIENT

Claire Mackin

Liver: Submitted are 2 excellent videos of aspirates collected from the liver in Claire. There are prominent hepatocytes in most of the videos. The hepatocytes demonstrate vacuolization with slight granularity. There is slight anisocytosis and anisokaryosis. There are prominent neutrophils and scattered lymphocytes throughout the collection. Some of these cells are associated with hepatocytes. Malignant characteristics are not identified.

SPECIES

Canine

Spleen: Submitted are 4 excellent videos of moderate collections of cells from the spleen in Claire. The cellularity is mixed with prominent neutrophils throughout the fields. There are scattered lymphoid cells and scattered nucleated red blood cells throughout the collection. Platelet aggregates are prominent. There are some lymphocytes and there is some connective tissue stroma but no significant malignant change or sepsis is identified. Inflammation is the major process.

BREED

Pitbull Mix

INTERPRETATION OF THE FINDINGS & FURTHER RECOMMENDATIONS

Liver - Hepatocellular vacuolization consistent with vacuolar hepatopathy and mild inflammation.
Spleen - Chronic suppurative splenitis with extra medullary hematopoiesis and prominence platelets suggesting acute hemorrhage.

SEX

Female Spayed

COMMENTS

The changes in the spleen suggest inflammation. The hemorrhage is due to the aspiration procedure and collection of red blood cells and platelets with inflammatory cells. There is a suggestion of inflammation in the spleen but no suggestion of malignancy or sepsis. This inflammation could be from any systemic process or some type of inflammation in the pancreas or intestine.

AGE

12y5m

The changes in the liver suggested metabolic liver changes. I wonder about the possibility of canine Cushing's syndrome and the possibility of psychogenic water intake. Very likely there is some type of abdominal discomfort or pain resulting in a psychogenic water intake if that is the problem. There is no suggestion of sepsis or malignancy in these tissues. Any changes in these tissues appear to be occurring secondarily and not as a primary process. Thus a guarded prognosis is warranted since the underlying process has not been identified.

WEIGHT

75#

HOSPITAL NAME

Animal Care Centers
Flanders

REFERRING VET

Dr. Hallihan

INVOICE NUMBER

888



DATE

2/7/23

INTERPRETED BY

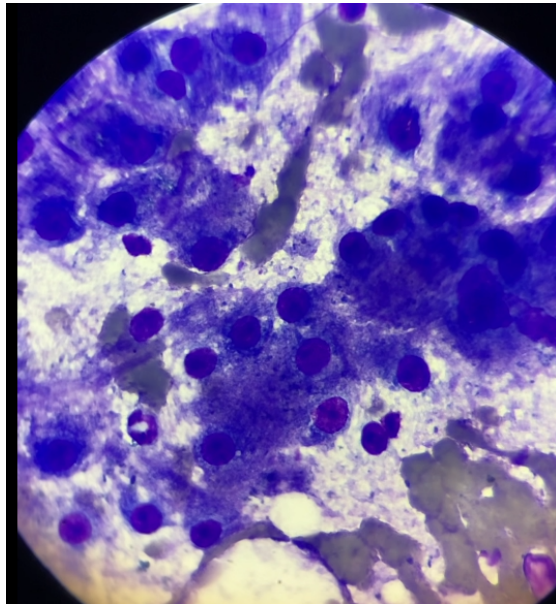
L.D. McGill, DVM,
Ph.D, DACVP

PATIENT

Claire Mackin

SPECIES

Canine



BREED

Pitbull Mix

SEX

Female Spayed

AGE

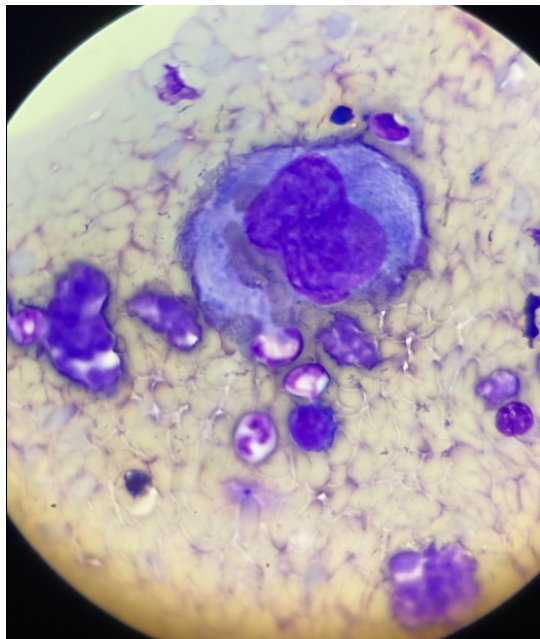
12y5m

WEIGHT

75#

HOSPITAL NAME

Animal Care Centers
Flanders



REFERRING VET

Dr. Hallihan

INVOICE NUMBER

888

Image shows hepatocytes with vacuolization and a mixture of inflammatory cells in the collection from Claire. Malignant characteristics are not observed.

Image shows a mixture of cells with neutrophils, a megakaryocyte and nucleated RBCs collected from the spleen in Claire. The purple clumps are platelets. Neutrophils were more prominent in other fields.



DATE 2/7/23 The information and recommendations provided are based on the images presented by the referring veterinarian. No evaluation can be communicated regarding pathology that was not visible in the image/video clips provided.

INTERPRETED BY L.D. McGill, DVM, Ph.D., DACVP Thank you for this referral. If the clinical or image interpretation does not parallel your findings or if I can be of any further assistance please contact me.

L.D. McGill, DVM,
Ph.D., DACVP

L.D. McGill, DVM, Ph.D., DACVP
8288 Top of the World Drive
Cottonwood Heights, UT 84121
ldmcgill.vetpath@gmail.com
cell: 801-865-1220

PATIENT

Claire Mackin

SPECIES

Canine

BREED

Pitbull Mix

SEX

Female Spayed

AGE

12y5m

WEIGHT

75#

HOSPITAL NAME

Animal Care Centers
Flanders

REFERRING VET

Dr. Hallihan

INVOICE NUMBER

888