



DATE PRESENTING CLINICAL SIGNS

2/28/23

Mass in liver-FNA L sided mass carcinoma vs granuloma

INTERPRETED BY CYTOLOGY SUBMISSION

L.D. McGill, DVM,
Ph.D, DACVP

FNA of Liver

PATIENT OBSERVATIONS

Patrick Ambrogi

Liver: Submitted are 7 excellent images of aggregates of hepatocytes collected from the liver in Patrick. The hepatocytes are piled upon each other with rather uniform nuclei. This cellularity is rather uniform and solid. Characteristics of malignancy are not identified. Other cellular infiltrations are not identified. There is no suggestion of inflammation in this collection. The cellularity suggests low-grade proliferation.

SPECIES

Canine

INTERPRETATION OF THE FINDINGS & FURTHER RECOMMENDATIONS

BREED

Irish Setter

Liver - Suggestive of nodular hyperplasia or low grade hepatocellular adenoma.

SEX COMMENTS

Male

There is no suggestion of inflammation and thus a granuloma is not part of the process. There is some suggestion of cellular piling up which can occur in nodular hyperplasia or a very low grade proliferative process in the liver. There is no suggestion of malignancy or sepsis in this collection of images. Exploratory and biopsy will be required to confirm the cellular proliferation. Cytologically it has a low-grade to benign appearance. A guarded prognosis is warranted until confirmation of the cellularity can be undertaken.

AGE

11y

WEIGHT

75lbs

HOSPITAL NAME

Rockaway Animal
Hospital

REFERRING VET

Dr. Maniar

INVOICE NUMBER

40675



DATE

2/28/23

INTERPRETED BY

L.D. McGill, DVM,
Ph.D, DACVP

PATIENT

Patrick Ambrogi

SPECIES

Canine

BREED

Irish Setter

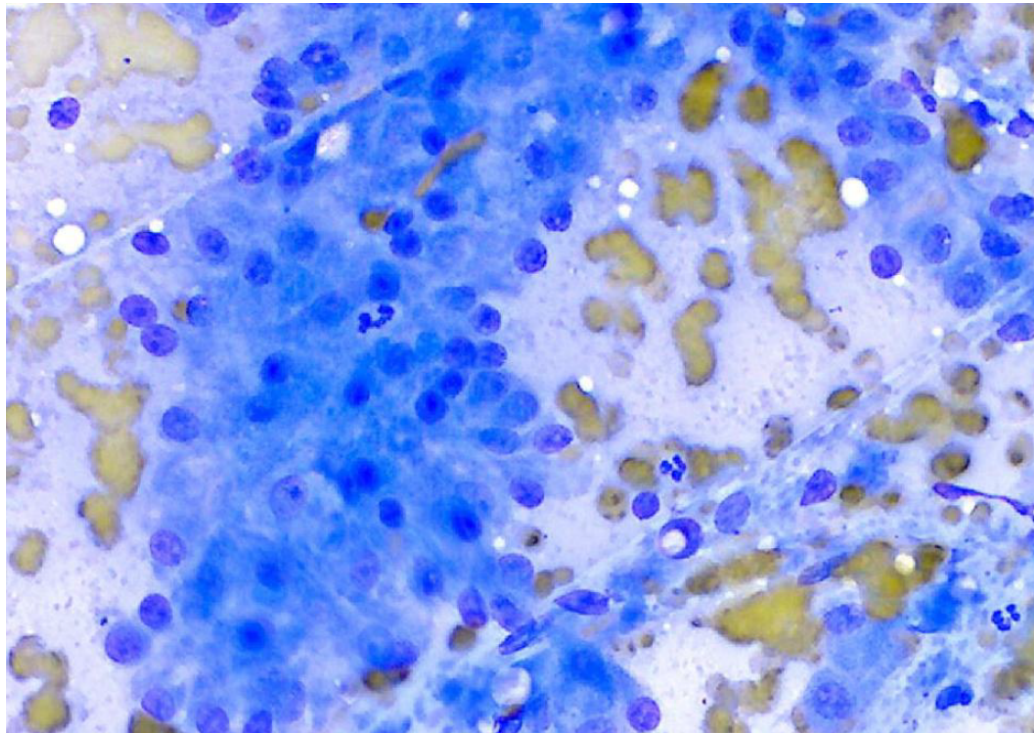


Image shows a representative collection of hepatocytes with rather uniform nuclei collected from Patrick. There are a few neutrophils associated with the hepatocytes.

SEX

Male

The information and recommendations provided are based on the images presented by the referring veterinarian. No evaluation can be communicated regarding pathology that was not visible in the image/video clips provided.

AGE

11y

Thank you for this referral. If the clinical or image interpretation does not parallel your findings or if I can be of any further assistance, please contact me.

WEIGHT

75lbs

L.D. McGill, DVM, Ph.D., DACVP
8288 Top of the World Drive
Cottonwood Heights, UT 84121
ldmcgill.vetpath@gmail.com
cell: 801-865-1220

HOSPITAL NAME

Rockaway Animal
Hospital

REFERRING VET

Dr. Maniar

INVOICE NUMBER

40675