



**DATE PRESENTING CLINICAL SIGNS**

2/28/23

Small 8mm pink raised mass in left axillary area.

**CYTOLOGY SUBMISSION**

Left axillary skin mass

**INTERPRETED BY**

L.D. McGill, DVM, Ph.D,  
DACVP

**OBSERVATIONS**

Left axillary skin mass: Submitted are 6 videos that are slightly out of focus of good collections of cells from the left axillary skin mass on Beast. The cellularity is mixed with large numbers of neutrophils. Macrophages are scattered throughout and there are a few lymphocytes. Some of the lymphocytes are large but most are small and mature. There are scattered degenerate cells and scattered adipocytes. Malignant characteristics are not identified.

**PATIENT**

Beast Bryant

**INTERPRETATION OF THE FINDINGS & FURTHER RECOMMENDATIONS**

Left axillary skin mass - Pyogranulomatous inflammation with mild necrosis.

**SPECIES COMMENTS**

Canine

The cellularity is mixed and characteristic. There are large numbers of neutrophils with scattered macrophages. There is no suggestion of malignancy or sepsis. This type of reaction is common with ruptured epidermal inclusion cysts or other follicular cyst or common with foreign body penetration. The lymphoid cells suggest some antigenicity but this can be from many different processes. Excision of the lesion is encouraged however anti-inflammatory therapy may be beneficial in decreasing the size of the mass. A good if completely excised prognosis is expected in my opinion.

BREED

Pitbull

\*Remember when videoing to make certain the image is in focus on the camera, not the microscope. These images are slightly out of focus but readable.

**SEX**

Male Neutered

**AGE**

3y

**WEIGHT**

79.5 lbs

**HOSPITAL NAME**

Central Veterinary  
Hospital

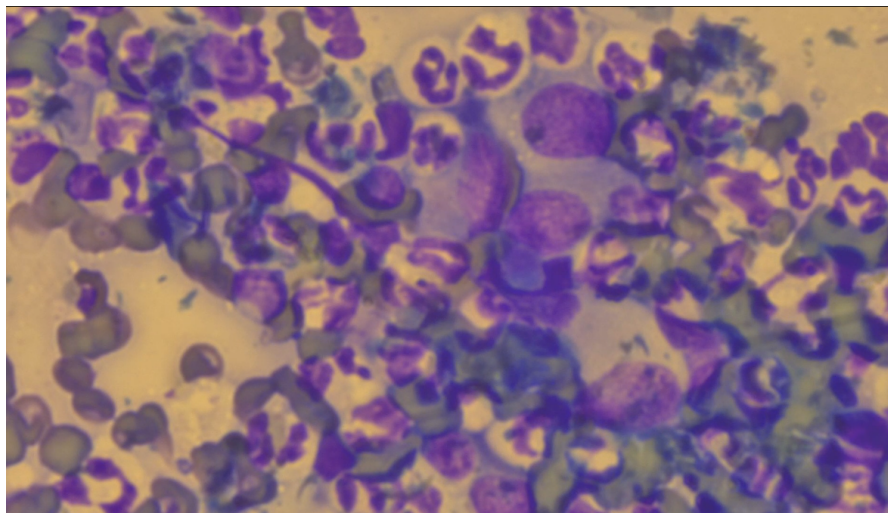


Image shows a slightly out of focus collection of cells from the skin mass on Beast. Note the neutrophils and intermixed macrophages.

**REFERRING VET**

Dr. St. Sir

The information and recommendations provided are based on the images presented by the referring veterinarian. No evaluation can be communicated regarding pathology that was not visible in the image/video clips provided.

**INVOICE NUMBER**

899



**DATE** Thank you for this referral. If the clinical or image interpretation does not parallel your findings or if I can be of any further assistance please contact me.

2/28/23

**INTERPRETED BY**

**L.D. McGill, DVM, Ph.D., DACVP**

8288 Top of the World Drive  
Cottonwood Heights, UT 84121  
ldmcgill.vetpath@gmail.com  
cell: 801-865-1220

L.D. McGill, DVM, Ph.D,  
DACVP

**PATIENT**

Beast Bryant

**SPECIES**

Canine

**BREED**

Pitbull

**SEX**

Male Neutered

**AGE**

3y

**WEIGHT**

79.5 lbs

**HOSPITAL NAME**

Central Veterinary  
Hospital

**REFERRING VET**

Dr. St. Sir

**INVOICE NUMBER**

899