



DATE PRESENTING CLINICAL SIGNS

2/28/23

Patient presented 2/27/23 for mammary mass and ear infection. Mammary mass large and pedunculated on the left side cranially. Mass first noted on exam 11/9/22.

INTERPRETED BY

CYTOLOGY SUBMISSION

Mammary mass

L.D. McGill, DVM, Ph.D,
DACVP

OBSERVATIONS

Mammary mass: Submitted are 20 excellent images of cells collected from the mammary mass on Baby. The cellularity is characteristic with massive numbers of metachromatic to purple granules in most of the cells. Those granules are also scattered throughout the surrounding background material. There are very few other inflammatory cells that include neutrophils and macrophages. Degenerate debris is prominent. The metachromatic granules confirm mast cell characteristics.

PATIENT

Baby Geer

INTERPRETATION OF THE FINDINGS & FURTHER RECOMMENDATIONS

Mammary mass - Mast cell tumor

SPECIES

Canine

COMMENTS

This is a characteristic mast cell tumor with many of the cells very well granulated. This suggests a low-grade mast cell tumor. This growth will be either grade 1 or grade 2. In other classifications, it will be a low-grade. Degeneration and inflammation are secondary. This is an excellent collection of mast cells and wide excision of the lesion is encouraged. There are new chemotherapeutic products you can attempt to utilize if you wish. Mast cell tumors always require a guarded prognosis but if they can be completely excised, then a favorable prognosis is possible. Baby should be continually monitored for independent growth in other locations.

BREED

American Bully

SEX

Female

AGE

10/1/2016

WEIGHT

64.5 lb

HOSPITAL NAME

Central Veterinary
Hospital

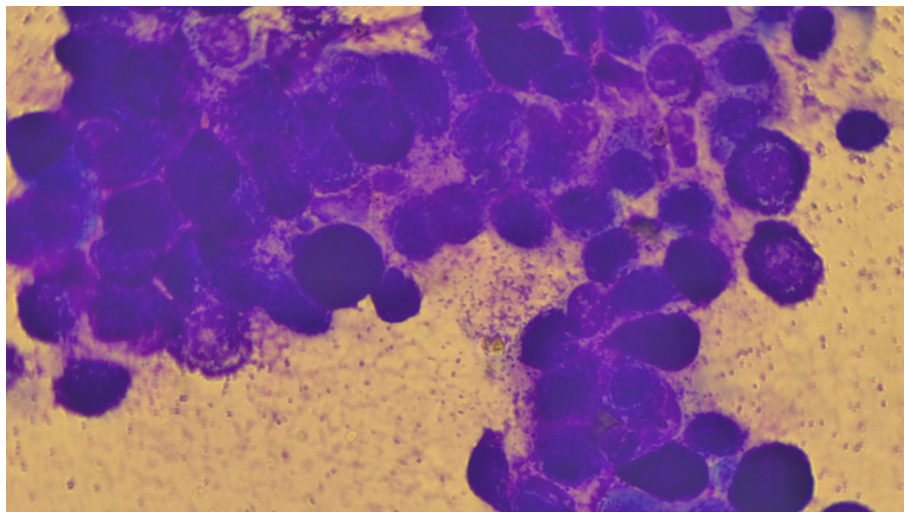


Image shows a group of well granulated mast cells with a granular background collected from the skin lesion on Baby. There are very few inflammatory cells.

REFERRING VET

Dr. St. Sir

The information and recommendations provided are based on the images presented by the referring veterinarian. No evaluation can be communicated regarding pathology that was not visible in the image/video clips provided.

INVOICE NUMBER

900

Thank you for this referral. If the clinical or image interpretation does not parallel your findings or if I



DATE can be of any further assistance please contact me.

2/28/23

INTERPRETED BY

L.D. McGill, DVM, Ph.D,
DACVP

L.D. McGill, DVM, Ph.D., DACVP
8288 Top of the World Drive
Cottonwood Heights, UT 84121
ldmcgill.vetpath@gmail.com
cell: 801-865-1220

PATIENT

Baby Geer

SPECIES

Canine

BREED

American Bully

SEX

Female

AGE

10/1/2016

WEIGHT

64.5 lb

HOSPITAL NAME

Central Veterinary
Hospital

REFERRING VET

Dr. St. Sir

INVOICE NUMBER

900