



**DATE PRESENTING CLINICAL SIGNS**

2/25/22  
Appears to be highly suggestive of neoplasia. O would like to have the fna completed for confirmation. We will find out if there is any treatment options but prognosis is guarded.

**INTERPRETED BY CYTOLOGY SUBMISSION**

L.D. McGill, DVM,  
Ph.D, DACVP

Pylorus

**OBSERVATIONS**

Pylorus: Submitted are 2 videos of minimal to moderate collections of cells from the pylorus in Jock. The cellularity is scattered throughout large numbers of RBCs. The majority of the cells are eosinophils with scattered neutrophils and lymphocytes. Some of the lymphocytes are reactive. Cells with malignant criteria are not identified. There is some degenerate debris present.

**PATIENT**

Jock McCorkle

**INTERPRETATION OF THE FINDINGS & FURTHER RECOMMENDATIONS**

Pylorus - Moderate eosinophilic inflammation with no evidence of neoplasia.

**SPECIES**

Canine

**COMMENTS**

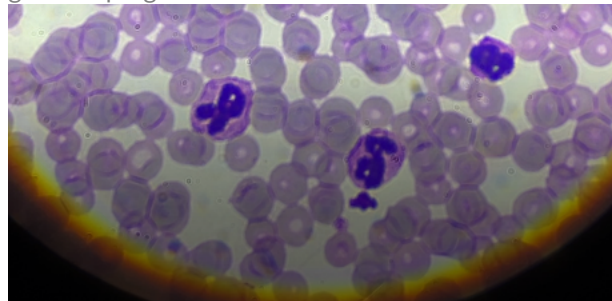
The cellularity in these videos is most consistent with a moderate to severe eosinophilic inflammatory response with the secondary involvement of neutrophils and lymphocytes. This could suggest an eosinophilic inflammatory reaction or even a parasitic response in this region. Treatment for allergy and parasites is encouraged. There is a possibility that neoplasia could be present and this type of reaction would be secondary but not primary. If problems continue, and further diagnostics are required, then exploratory and surgical biopsy would be encouraged. Treatment for eosinophilic inflammation is encouraged prior to any surgical intervention. A guarded prognosis is warranted.

**BREED**

Jack Russell Terrier

**SEX**

Male Neutered



**AGE**

12y

**WEIGHT**

20.6lbs

Image shows a good group of eosinophils collected from the pylorus in Jock. Other cells are present but these are the most numerous cells observed.

**HOSPITAL NAME**

Pleasant Hill Animal  
Hospital

The information and recommendations provided are based on the images presented by the referring veterinarian. No evaluation can be communicated regarding pathology that was not visible in the image/video clips provided.

Thank you for this referral. If the clinical or image interpretation does not parallel your findings or if I can be of any further assistance please contact me.

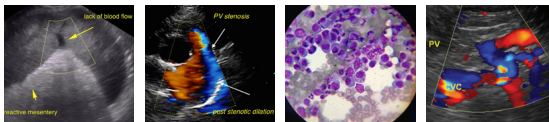
**REFERRING VET**

Dr. Larsen

L.D. McGill, DVM, Ph.D., DACVP  
8288 Top of the World Drive  
Cottonwood Heights, UT 84121  
ldmcgill.vetpath@gmail.com  
cell: 801-865-1220

**INVOICE NUMBER**

678



**DATE**

2/25/22

**INTERPRETED BY**

L.D. McGill, DVM,  
Ph.D, DACVP

**PATIENT**

Jock McCorkle

**SPECIES**

Canine

**BREED**

Jack Russell Terrier

**SEX**

Male Neutered

**AGE**

12y

**WEIGHT**

20.6lbs

**HOSPITAL NAME**

Pleasant Hill Animal  
Hospital

**REFERRING VET**

Dr. Larsen

**INVOICE NUMBER**

678