



DATE PRESENTING CLINICAL SIGNS

2/24/23

Patient presented 2/24/23 for LF lateral digit red raised bloody mass. Mass is on dorsal aspect just behind nail. Mass approx the size of a chickpea. Has been present ~ 6 weeks.

CYTOLOGY SUBMISSION

INTERPRETED BY

Toe skin lesion

L.D. McGill, DVM,
Ph.D, DACVP

OBSERVATIONS

Toe skin lesion: Submitted are 24 excellent images of cells collected from the toe skin lesion on Lucy. The cellularity is mainly erythrocytes with scattered nucleated cells. Most of the nucleated cells are mononuclear cells that have a histiocytic pattern with some cells demonstrating a lymphocytic pattern. Scattered neutrophils are present. There are some cells that suggest macrophages. Malignant characteristics are not identified nor is there evidence of sepsis.

PATIENT

Lucy Pulliam

INTERPRETATION OF THE FINDINGS & FURTHER RECOMMENDATIONS

Toe skin lesion - Pyogranulomatous inflammation with some cells suggesting histiocytic patterns.

SPECIES

Canine

COMMENTS

The cellularity suggests the possibility of a histiocytoma with secondary chronic inflammation. There is a possibility that this could be chronic pyogranulomatous inflammation from a foreign body penetration or other process in the region. Aggressive malignant changes are not identified nor can we identify infection. There is prominent inflammation and trauma. The cellularity is altered by the hemodilution of the collection. The aspiration may have been a little strong to result in large numbers of red blood cells. Continued monitoring of the lesion or excision of the mass is encouraged. A good if completely excised prognosis is warranted.

BREED

Boxer

SEX

Female Spayed

AGE

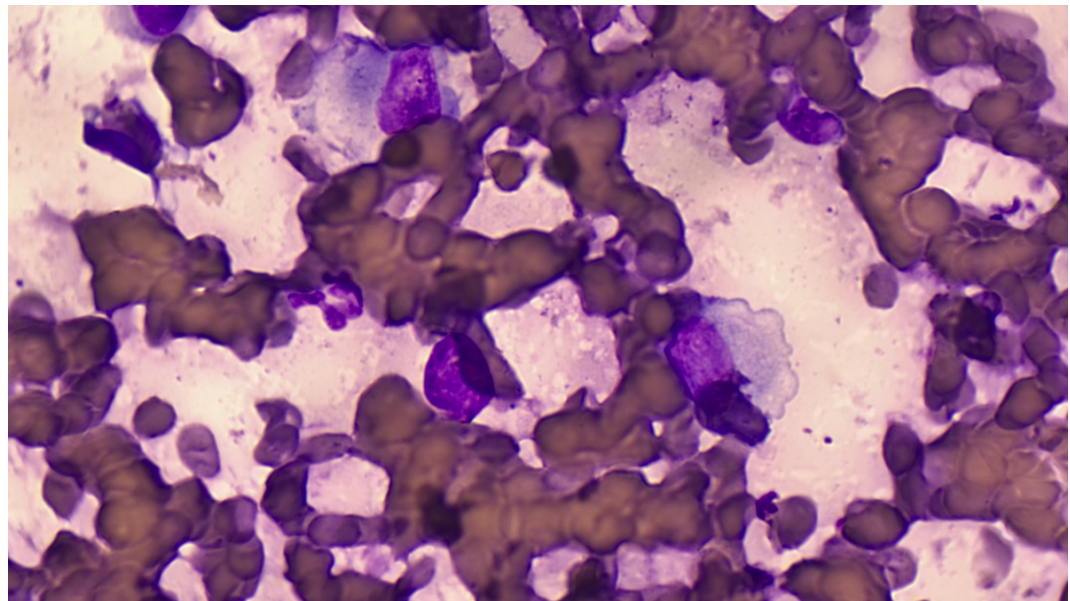
~3y

WEIGHT

58.1 lbs

HOSPITAL NAME

Rotterdam Veterinary
Hospital



REFERRING VET

Dr. Scarpinato

Image shows a large number of RBCs with a neutrophil, lymphocyte and at least 2 histiocytic cells collected from the toe skin lesion on Lucy. The RBCs support a strong aspiration of negative pressure.

The information and recommendations provided are based on the images presented by the referring veterinarian. No evaluation can be communicated regarding pathology that was not visible in the image/video clips provided.

INVOICE NUMBER

898



DATE

2/24/23

Thank you for this referral. If the clinical or image interpretation does not parallel your findings or if I can be of any further assistance please contact me.

INTERPRETED BY

L.D. McGill, DVM,
Ph.D, DACVP

L.D. McGill, DVM, Ph.D., DACVP
8288 Top of the World Drive
Cottonwood Heights, UT 84121
ldmcgill.vetpath@gmail.com
cell: 801-865-1220

PATIENT

Lucy Pulliam

SPECIES

Canine

BREED

Boxer

SEX

Female Spayed

AGE

~3y

WEIGHT

58.1 lbs

HOSPITAL NAME

Rotterdam Veterinary
Hospital

REFERRING VET

Dr. Scarpinato

INVOICE NUMBER

898