

**DATE PRESENTING CLINICAL SIGNS**

2/24/23

History: P has been quickly losing weight, occasional vomiting of undigested food, not eating as much for 1 to 2 week duration.  
On PE, P underweight, generalized muscle atrophy, dehydrated, greasy unkempt hair coat.  
Ping pong ball sized firm mass palpated in the mid ventral abdomen.

**INTERPRETED BY**

L.D. McGill, DVM,  
Ph.D, DACVP

TP: 5.4  
ALP 349  
GGT 14  
Tbili: 8.7  
CBC unremarkable  
lipase: normal  
TT4, U/A, and Pt/PTT pending  
Current Medications  
Cerenia (10mg/ml) 0.3ml SQ, LRS SQF 100ml

**PATIENT**

Coco Hill

**SPECIES**

Feline

**CYTOLOGY SUBMISSION**  
FNA of Lymph Node

**BREED**

DSH

**OBSERVATIONS**  
Lymph node: Submitted are 3 excellent videos of minimal cellular collections from the lymph node in Coco. The cellularity includes scattered lymphoid cells, many of which are small mature lymphocytes. There are reactive lymphoid cells and eosinophils in the collection. Smudge debris is prominent in scattered areas of the collection. Malignant characteristics are not identified.

**SEX**

FS

**INTERPRETATION OF THE FINDINGS & FURTHER RECOMMENDATIONS**

**AGE**

9 yrs

Lymph node - Minimal cellularity with a suggestion of eosinophilic lymphadenitis.

**COMMENTS**

**WEIGHT**

6.7 lbs

The cellularity in the few nucleated cells present include a good number of eosinophils associated with a mixed collection of lymphocytes. Many of the lymphocytes are small lymphocytes with reactive lymphoid cells also. I was unable to identify any changes that would support malignancy or lymphoma. In this instance I am concerned that there is some type of an eosinophilic inflammatory process, but lymphoma cannot be ruled out. Intestinal lymphoma often does not involve the mesenteric lymph nodes as this sample appears to be derived. A guarded prognosis is warranted since the underlying process is not identified.

**HOSPITAL NAME**

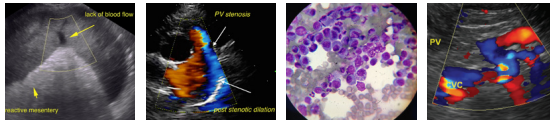
West Salem AC

**REFERRING VET**

Dr. Crane

**INVOICE NUMBER**

40669



**DATE**

2/24/23

**INTERPRETED BY**

L.D. McGill, DVM,  
Ph.D., DACVP

**PATIENT**

Coco Hill

**SPECIES**

Feline

**BREED**

DSH

**SEX**

FS

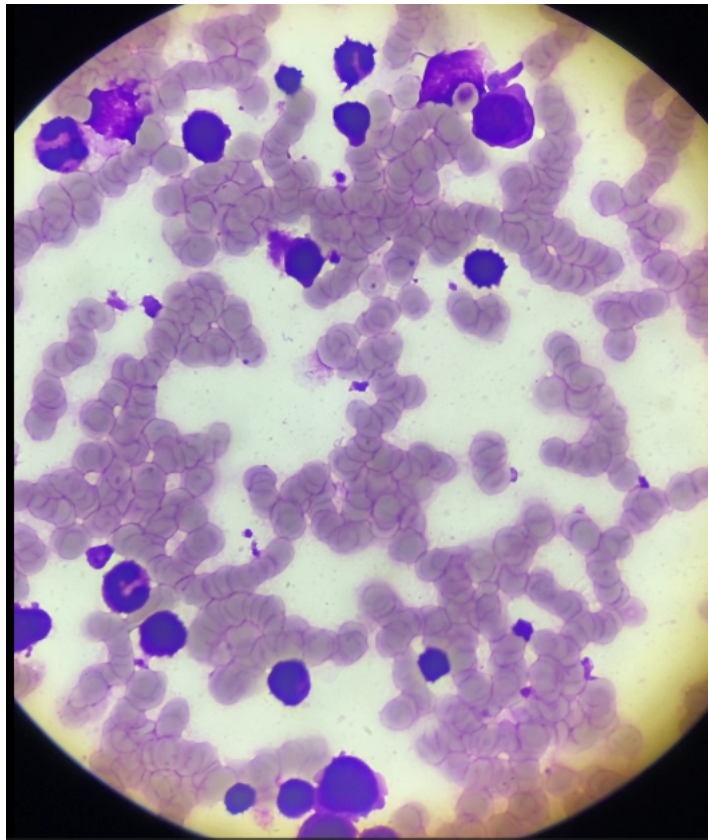


Image shows a representative collection of cells from the lymph node in Coco. Eosinophils are prominent.

**AGE**

9 yrs

The information and recommendations provided are based on the images presented by the referring veterinarian. No evaluation can be communicated regarding pathology that was not visible in the image/video clips provided.

**WEIGHT**

6.7 lbs

Thank you for this referral. If the clinical or image interpretation does not parallel your findings or if I can be of any further assistance, please contact me.

**HOSPITAL NAME**

West Salem AC

L.D. McGill, DVM, Ph.D., DACVP  
8288 Top of the World Drive  
Cottonwood Heights, UT 84121  
ldmcgill.vetpath@gmail.com  
cell: 801-865-1220

**REFERRING VET**

Dr. Crane

**INVOICE NUMBER**

40669