



DATE PRESENTING CLINICAL SIGNS

2/24/23 Previous Hx of Soft Tissue Sarcoma in 2019
Owner noticed enlarged Mandibular LN's over weekend.
Dog feeling fine otherwise

INTERPRETED BY

L.D. McGill, DVM,
Ph.D, DACVP

Abdominal U/S: Spleen has a couple small (1cm diameter) hypoechoic masses and 1 larger (3x3cm) hetegenous mass that expands the capsule. FNA is of this larger mass.
Mandibular LN's are markedly enlarged; the other peripheral LN's are not as prominent.

CYTOLOGY SUBMISSION

FNA of Lymph Node

PATIENT

Buddy Wise

OBSERVATIONS

Lymph node: Submitted are 4 excellent videos of excellent collections of cells from the submandibular lymph node in Buddy. The cellularity consists of large numbers of lymphoid cells. There are scattered small lymphocytes in the collection but the majority of the cells are large irregular lymphoid cells with prominent nucleoli. The nucleoli are irregular in size and shape and in some instances are multiple. There are scattered neutrophils in the collection. The uniformity of these cells suggests neoplasia.

SPECIES

Canine

BREED

Labrador Retriever

INTERPRETATION OF THE FINDINGS & FURTHER RECOMMENDATIONS

Lymph node - Increased numbers of atypical lymphoid cells suggestive of a high-grade lymphoma.

COMMENTS

SEX
Male Neutered

The cellularity in this collection strongly suggests a high-grade lymphoma in these cells. There are prominent nucleoli, and they are irregular. There are very few small cells. The irregular cells are approaching 80 to 90% of the cells in the collection. Confirmation will require additional testing. If chemotherapy is contemplated, then immunophenotyping of the cells to confirm the specific cell type may be beneficial for prognosis. The slides may be submitted for PARR testing or new slides that are not stained can be submitted for immunocytochemistry staining. Flow cytometry can be beneficial but will require a repeat collection of cells prior to submission to the laboratory. Contacting the laboratory to confirm how to submit flow cytometry samples is encouraged. A guarded to unfavorable prognosis is warranted in my opinion.

AGE

10 years

WEIGHT

96lbs

HOSPITAL NAME

Franklin Animal Clinic
Inc.

REFERRING VET

Dr. Sam Doverspike

INVOICE NUMBER

40670



DATE

2/24/23

INTERPRETED BY

L.D. McGill, DVM,
Ph.D, DACVP

PATIENT

Buddy Wise

SPECIES

Canine

BREED

Labrador Retriever

SEX

Male Neutered

AGE

10 years

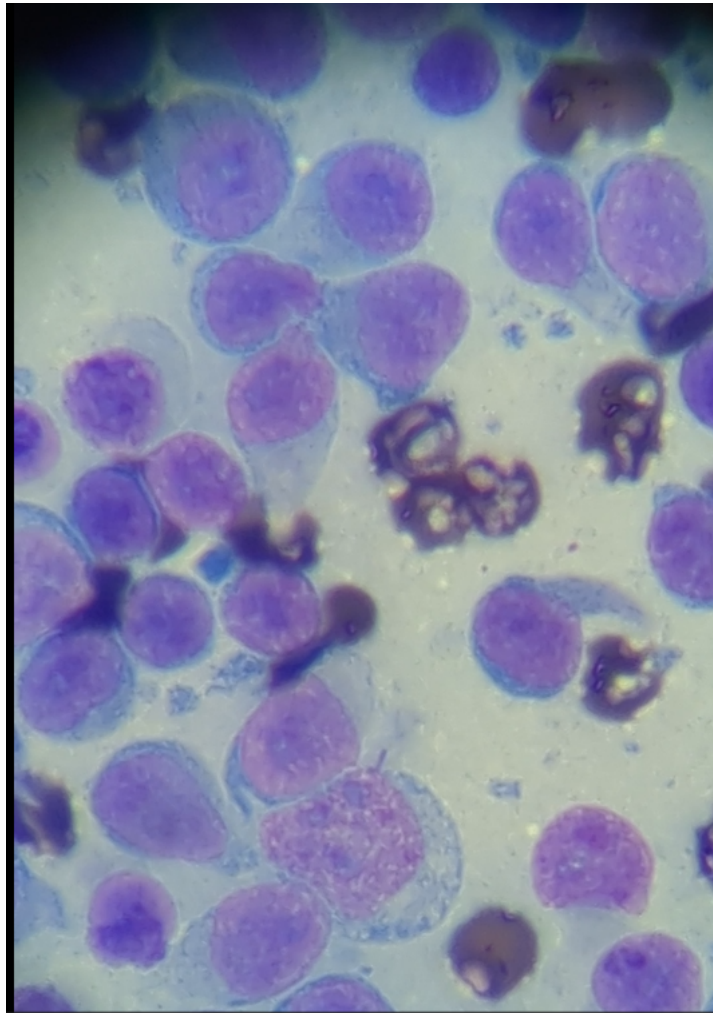


Image shows a group of cells collected from the lymph node in Buddy. Note the prominent nucleoli and large cells with rare small mature cells.

WEIGHT

96lbs

The information and recommendations provided are based on the images presented by the referring veterinarian. No evaluation can be communicated regarding pathology that was not visible in the image/video clips provided.

HOSPITAL NAME

Franklin Animal Clinic
Inc.

Thank you for this referral. If the clinical or image interpretation does not parallel your findings or if I can be of any further assistance, please contact me.

REFERRING VET

Dr. Sam Doverspike

L.D. McGill, DVM, Ph.D., DACVP
8288 Top of the World Drive
Cottonwood Heights, UT 84121
ldmcgill.vetpath@gmail.com
cell: 801-865-1220

INVOICE NUMBER

40670



DATE

2/24/23

INTERPRETED BY

L.D. McGill, DVM,
Ph.D, DACVP

PATIENT

Buddy Wise

SPECIES

Canine

BREED

Labrador Retriever

SEX

Male Neutered

AGE

10 years

WEIGHT

96lbs

HOSPITAL NAME

Franklin Animal Clinic
Inc.

REFERRING VET

Dr. Sam Doverspike

INVOICE NUMBER

40670