



**DATE PRESENTING CLINICAL SIGNS**

2/23/22

The owner noticed that the cat's abdomen is getting enlarged. Nunu is not neutered so she thought that she may be pregnant. A mass effect was seen in the abdomen in the X-Ray and a large cystic mass was seen in the US in the abdomen. There was a nodule proximal to the last mammary gland. The FNA was done from this and submitted for analysis

**INTERPRETED BY**

PE: Nothing abnormal was detected except abdominal enlargement. Rest of the tests were not done

L.D. McGill, DVM,  
Ph.D, DACVP

**CYTOLOGY SUBMISSION**

Aspiration from near mammary gland

**PATIENT**

Nunu Mousa

**OBSERVATIONS**

Aspiration from near the mammary gland: Submitted are several images of cells collected from from near the mammary gland on Nunu. There are scattered inflammatory cells that are neutrophils; there are some small packets of round nuclei. These nuclei are naked nuclei with minimal cytoplasm. There are scattered aggregates of platelets and degenerate debris.

**SPECIES**

Feline

**INTERPRETATION OF THE FINDINGS & FURTHER RECOMMENDATIONS**

Aspiration from near the mammary gland - Naked nuclei with scattered inflammatory cells.

**BREED**

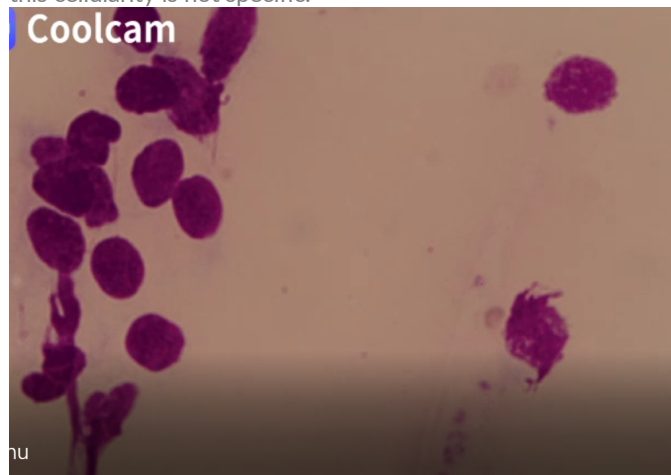
Himalayan

**COMMENTS**

There are some cells in this collection but what type of cells are present is difficult to confirm. There are scattered neutrophils. The cells could be lymphocytes or mammary gland epithelial cells. I'm concerned that this may be from a location of necrosis within some type of the mass. I am unable to confirm malignancy or sepsis. Repeat collection either by aspiration or by biopsy is encouraged since this cellularity is not specific.

**SEX**

Female



**AGE**

11y

**WEIGHT**

4.78kg

**HOSPITAL NAME**

City Veterinary Clinic  
Alain

Image shows a field of naked nuclei collected from the mammary region on Nunu. The cells are not identifiable.

**REFERRING VET**

Dr. Inam ul haq

The information and recommendations provided are based on the images presented by the referring veterinarian. No evaluation can be communicated regarding pathology that was not visible in the image/video clips provided.

**INVOICE NUMBER**

677

Thank you for this referral. If the clinical or image interpretation does not parallel your findings or if I can be of any further assistance please contact me.



**DATE**

2/23/22 **L.D. McGill, DVM, Ph.D., DACVP**  
8288 Top of the World Drive  
Cottonwood Heights, UT 84121  
ldmcgill.vetpath@gmail.com  
cell: 801-865-1220

**INTERPRETED BY**

L.D. McGill, DVM,  
Ph.D, DACVP

**PATIENT**

Nunu Mousa

**SPECIES**

Feline

**BREED**

Himalayan

**SEX**

Female

**AGE**

11y

**WEIGHT**

4.78kg

**HOSPITAL NAME**

City Veterinary Clinic  
Alain

**REFERRING VET**

Dr. Inam ul haq

**INVOICE NUMBER**

677