



**DATE PRESENTING CLINICAL SIGNS**

2/22/23

Multiple sites to be submitted. 1st set is intestinal wall. Patient presented for weight loss. Grade 3 heart murmur. Findings on u/s--thickened intestines, coarse enlarged liver and spleen, enlarged mesenteric lymph nodes.  
High fPL (11.5), 2+ protein in urine, 2+ ammonium phosphate crystals in urine

**INTERPRETED BY**

L.D. McGill, DVM,  
Ph.D, DACVP

**CYTOLOGY SUBMISSION**

FNA of Spleen

**PATIENT**

Patch OSC

**OBSERVATIONS**

Spleen: Submitted are 5 excellent videos of minimal collections of nucleated cells from the spleen in Patch. There is marked hemodilution throughout the smears. Scattered cells are present and there is a mixed cell collection. Eosinophils are identified with scattered neutrophils, lymphocytes and nucleated red blood cells. Malignant characteristics are not identified.

**SPECIES**

Feline

**INTERPRETATION OF THE FINDINGS & FURTHER RECOMMENDATIONS**

**BREED**

Spleen - Mixed cell collection with prominent eosinophils and mixed other cells.

**DSH**

**COMMENTS**

**SEX**

Male Neutered

The cellularity in the spleen includes eosinophils which were identified in the intestine. In this instance I am suspicious of an eosinophilic inflammatory process in Patch. There were no changes that would suggest neoplasia or sepsis. The changes are not characteristic of FIP but more likely an eosinophilic inflammatory process. This could be due to parasites, allergies or other eosinophilic stimulations.

**AGE**

7 yr

**WEIGHT**

8.9 #

**HOSPITAL NAME**

Central Veterinary  
Hospital

**REFERRING VET**

Dr. Anna St Sir

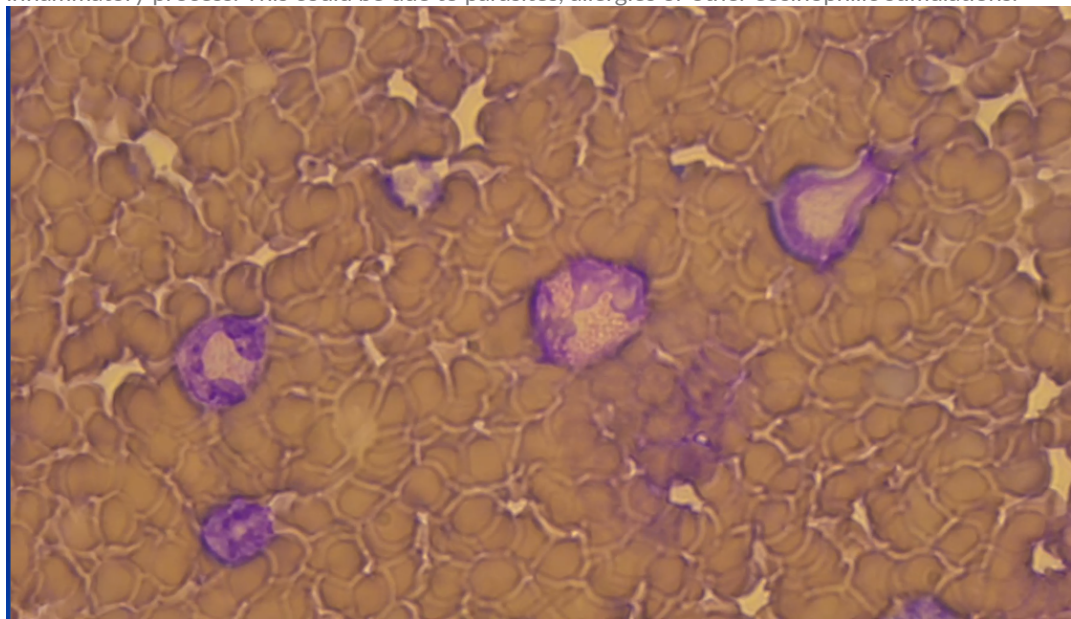


Image shows a group of 2 or 3 eosinophils with a probable small lymphocyte in the spleen in Patch. There are no malignant characteristics.

**INVOICE NUMBER**

40666



**DATE**

2/22/23

The information and recommendations provided are based on the images presented by the referring veterinarian. No evaluation can be communicated regarding pathology that was not visible in the image/video clips provided.

**INTERPRETED BY**

L.D. McGill, DVM,  
Ph.D, DACVP

Thank you for this referral. If the clinical or image interpretation does not parallel your findings or if I can be of any further assistance, please contact me.

**PATIENT**

Patch OSC

**L.D. McGill, DVM, Ph.D., DACVP**  
8288 Top of the World Drive  
Cottonwood Heights, UT 84121  
ldmcgill.vetpath@gmail.com  
cell: 801-865-1220

**SPECIES**

Feline

**BREED**

DSH

**SEX**

Male Neutered

**AGE**

7 yr

**WEIGHT**

8.9 #

**HOSPITAL NAME**

Central Veterinary  
Hospital

**REFERRING VET**

Dr. Anna St Sir

**INVOICE NUMBER**

40666