



DATE PRESENTING CLINICAL SIGNS

2/22/2022 History of prostatic nodule.

CYTOLOGY SUBMISSION
U/S-guided FNA of prostate.

INTERPRETED BY

L.D. McGill, DVM,
Ph.D, DACVP

OBSERVATIONS

Prostate: Submitted are 3 good videos and nine images of cells and material collected from the prostate in Kobe. The material on these slides is staining extremely dark. There are scattered neutrophils and rare structures that suggest epithelial cells. Some scattered structures suggest crystals. The dark staining structures cannot be identified as cells but may be degenerate debris or protein or even calcium. Malignant criteria are not identified.

PATIENT

Kobe Prizzi

INTERPRETATION OF THE FINDINGS & FURTHER RECOMMENDATIONS

Prostate - Necrotic debris with darkly stained material and scattered inflammatory cells.

SPECIES

Canine

COMMENTS

The cellularity is difficult to identify due to the dark staining of these collections. The more I continue to evaluate the images, I am not certain that the dark material is cellularity. It appears to be necrotic material with calcium in other changes. I certainly am unable to identify sepsis or neoplasia. Exploratory and marsupialization of this nodule may be beneficial. A biopsy may be more instructive of the real pathology at this location.

BREED

Maltipoo

SEX

Male neutered

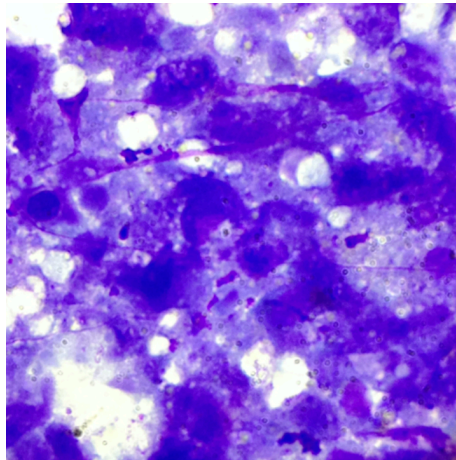
Image below shows a representative collection with scattered inflammatory cells aspirated from the prostate in Kobe. If the dark structures are cells, they are difficult to identify due to the dark staining.

AGE

11-year-old

WEIGHT

18 lbs



HOSPITAL NAME

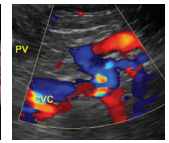
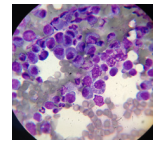
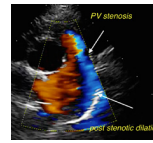
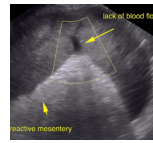
Franklin Lakes AH

REFERRING VET

Dr. Ward

The information and recommendations provided are based on the images presented by the referring veterinarian. No evaluation can be communicated regarding pathology that was not visible in the image/video clips provided.

Thank you for this referral. If the clinical or image interpretation does not parallel your findings or if I can be of any further assistance please contact me.



DATE L.D. McGill, DVM, Ph.D., DACVP

2/22/2022 8288 Top of the World Drive
Cottonwood Heights, UT 84121
ldmcgill.vetpath@gmail.com
cell: 801-865-1220

INTERPRETED BY

L.D. McGill, DVM,
Ph.D, DACVP

PATIENT

Kobe Prizzi

SPECIES

Canine

BREED

Maltipoo

SEX

Male neutered

AGE

11-year-old

WEIGHT

18 lbs

HOSPITAL NAME

Franklin Lakes AH

REFERRING VET

Dr. Ward