



DATE PRESENTING CLINICAL SIGNS

2/21/23

Abdominal mass, caudal abdominal mass, possibly associated with descending colon or section of bowel.
CBC - mon 0.04

INTERPRETED BY

L.D. McGill, DVM,
Ph.D, DACVP

CYTOLOGY SUBMISSION

FNA of Ileocecolic mass

PATIENT

Cuddles Gil

OBSERVATIONS

Ileocecolic mass: Submitted are 8 excellent videos of debris and minimal cellularity collected from the ileocecolic region in Cuddles. The cellularity, where preserved, consists of neutrophils, macrophages, some lymphocytes and mainly necrotic debris. Mucus is identified in some of the fields. Much of the material in the collection is amorphous and unidentifiable and very likely necrotic debris. Malignant characteristics are not identified.

SPECIES

Feline

INTERPRETATION OF THE FINDINGS & FURTHER RECOMMENDATIONS

Ileocecolic mass - Necrotic and pyogranulomatous collection.

BREED

Bombay

COMMENTS

With so much necrotic debris and mucus, I wonder about the possibility of a localized intestinal diverticulum with inflammation. I am unable to rule out the possibility of dry form FIP with a localized inflammatory response and necrosis. There is no suggestion of malignancy. In one field there was a suggestion of fungal material and I wondered about pythiosis. Exploratory and excision of the lesion appears to be the most likely potential for identifying and treating Cuddles. A guarded prognosis is definitely warranted.

SEX

Male Neutered

AGE

Not Provided

WEIGHT

11.1#

HOSPITAL NAME

Animal Paradise Hospital

REFERRING VET

Dr. Elshafie

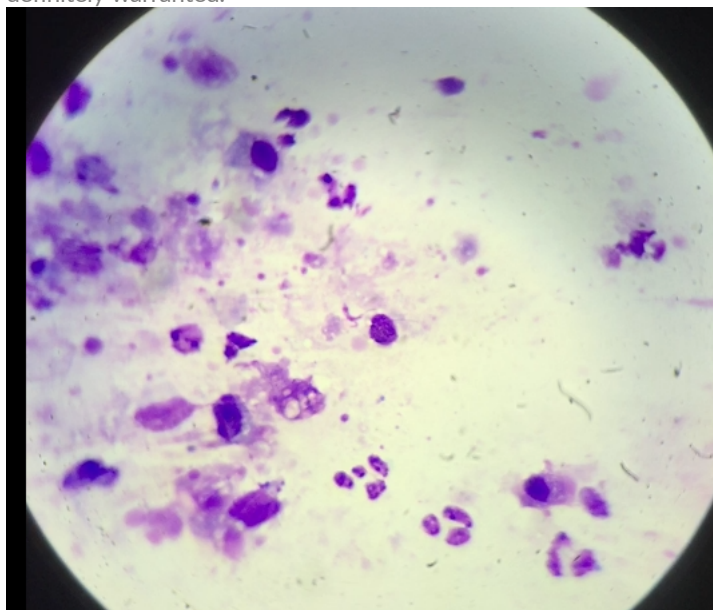


Image shows a representative collection of cells and debris from the mass in Cuddles. Neutrophils and macrophages are prominent in this image. There is prominent necrotic debris.

INVOICE NUMBER

40665



DATE

2/21/23

The information and recommendations provided are based on the images presented by the referring veterinarian. No evaluation can be communicated regarding pathology that was not visible in the image/video clips provided.

INTERPRETED BY

L.D. McGill, DVM,
Ph.D, DACVP

Thank you for this referral. If the clinical or image interpretation does not parallel your findings or if I can be of any further assistance, please contact me.

PATIENT

Cuddles Gil

L.D. McGill, DVM, Ph.D., DACVP
8288 Top of the World Drive
Cottonwood Heights, UT 84121
ldmcgill.vetpath@gmail.com
cell: 801-865-1220

SPECIES

Feline

BREED

Bombay

SEX

Male Neutered

AGE

Not Provided

WEIGHT

11.1#

HOSPITAL NAME

Animal Paradise Hospital

REFERRING VET

Dr. Elshafie

INVOICE NUMBER

40665