



DATE PRESENTING CLINICAL SIGNS

2/18/22

Lymphadenopathy

CYTOLOGY SUBMISSION

Lymph node

INTERPRETED BY

L.D. McGill, DVM,
Ph.D, DACVP

OBSERVATIONS

Lymph node aspirate: Submitted are 3 very good to excellent videos of cells collected from the lymph node tissue. The majority of the cells are lymphoid cells with nuclei that are 2 to 4 times the size of red blood cells. Many of the nuclei have nucleoli which are pleomorphic or even multiple. There are scattered macrophages and rare neutrophils in the collection. The lymphoid cells have minimal cytoplasm in many instances but other lymphoid cells have more prominent cytoplasm which is bluish gray. I observed 1 or 2 mitotic figures.

PATIENT

Karman Aalto

INTERPRETATION OF THE FINDINGS & FURTHER RECOMMENDATIONS

Lymph node - Increased numbers of atypical lymphoid cells strongly suggestive of early high-grade lymphoma.

SPECIES

Canine

COMMENTS

The cellularity in the excellent fields that have cells, strongly supports an early high-grade lymphoma. Confirmation can be undertaken with immunohistochemistry if desired. Follow-up biopsies may be beneficial. If chemotherapy is contemplated, immunophenotyping of the cells in this collection may be beneficial to identify cell type. This information may contribute to the prognosis. These slides may be submitted for PARR testing or biopsy and immunohistochemistry staining can be undertaken. Recollection for flow cytometry evaluation will be required if that testing is desired. You may wish to contact the laboratory to confirm the sample required for flow cytometry. With the cells observed in these videos, an unfavorable prognosis is warranted in my opinion. Karman may respond to chemotherapy and prolong life.

BREED

Golden Retriever

SEX

Female Spayed

AGE

11y

WEIGHT

78 lbs

HOSPITAL NAME

Bayshore Veterinary
Hospital

REFERRING VET

Dr. Hunt

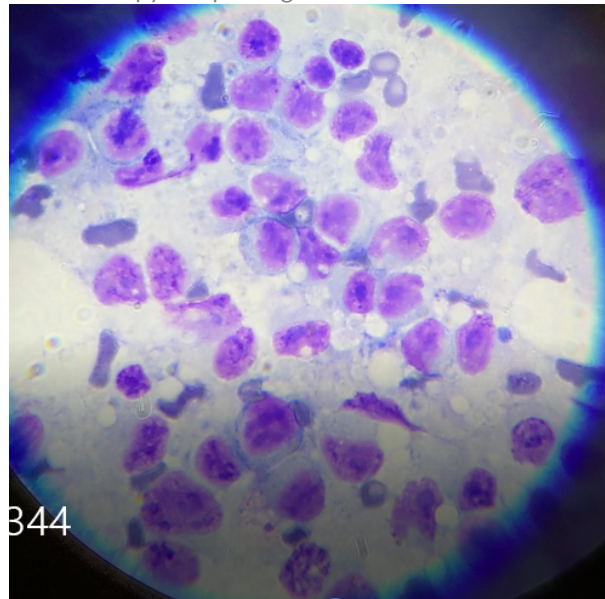


Image shows large lymphoid cells with prominent irregular nucleoli. There are 2 or 3 small lymphocytes in this image.

INVOICE NUMBER

674



DATE

2/18/22

The information and recommendations provided are based on the images presented by the referring veterinarian. No evaluation can be communicated regarding pathology that was not visible in the image/video clips provided.

INTERPRETED BY

L.D. McGill, DVM,
Ph.D., DACVP

Thank you for this referral. If the clinical or image interpretation does not parallel your findings or if I can be of any further assistance please contact me.

PATIENT

Karman Aalto

L.D. McGill, DVM, Ph.D., DACVP
8288 Top of the World Drive
Cottonwood Heights, UT 84121
ldmcgill.vetpath@gmail.com
cell: 801-865-1220

SPECIES

Canine

BREED

Golden Retriever

SEX

Female Spayed

AGE

11y

WEIGHT

78 lbs

HOSPITAL NAME

Bayshore Veterinary
Hospital

REFERRING VET

Dr. Hunt

INVOICE NUMBER

674