



DATE PRESENTING CLINICAL SIGNS

2/18/22 3 day history of enlarged LN, otherwise doing well.
Peripheral lymphadenopathy, diffuse. CBC- WNL (lymphocytes 1.16K/uL). Chemistry declined. Mild dental calculus. BCS 3.5/5.

INTERPRETED BY CYTOLOGY SUBMISSION

L.D. McGill, DVM,
Ph.D, DACVP Lymph node aspirate

OBSERVATIONS

Lymph node: Submitted are 6 excellent videos of excellent collections of cells from the lymph node in KJ. In all of the videos, there are quite large lymphoid cells. The lymphoid cells have minimal to moderate cytoplasm. The nuclei are 2 to 6 times the size of red blood cells. The nuclei have very irregular and even multiple nucleoli. Mitotic figures are observed. These large lymphoid cells are greater than 70% of the lymphoid cells in the collection.

PATIENT

KJ Nelson

INTERPRETATION OF THE FINDINGS & FURTHER RECOMMENDATIONS

SPECIES Lymph node - High-grade lymphoma

Canine

COMMENTS

The cellularity in this collection is characteristic of an aggressive lymphoma and thus I described it as a high grade lymphoma. The cells are quite large and irregular. The nucleoli are extremely pleomorphic and it is easy to identify mitotic figures. If chemotherapy is contemplated, immunophenotyping of the cells in this collection may be beneficial to identify cell type. This information may contribute to the prognosis. These slides may be submitted for PARR testing or biopsy and immunohistochemistry staining can be undertaken. Re-collection for flow cytometry evaluation will be required if that testing is desired. You may wish to contact the laboratory to confirm the sample required for flow cytometry. KJ may respond to some therapy but in the long run an unfavorable prognosis is likely.

BREED

Lab Mix

SEX

Female Spayed

AGE

10.5y

WEIGHT

43 lbs

HOSPITAL NAME

Ruidoso Animal Clinic

REFERRING VET

Dr. Thurston

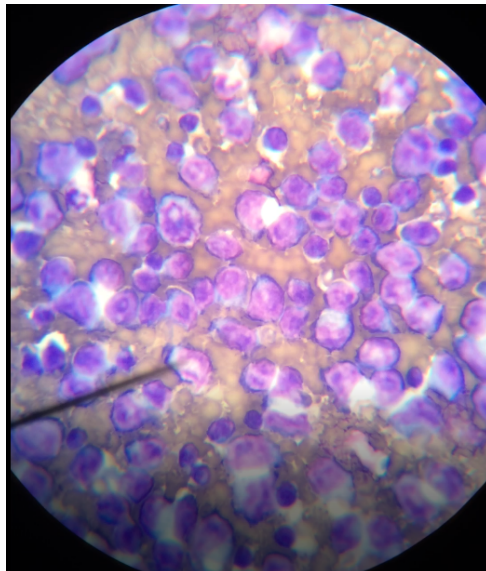


Image shows large lymphoid cells with a few small cells interspersed. Nucleoli are irregular and multiple. There is a mitotic figure in the upper center.

INVOICE NUMBER

675



DATE 2/18/22 The information and recommendations provided are based on the images presented by the referring veterinarian. No evaluation can be communicated regarding pathology that was not visible in the image/video clips provided.

INTERPRETED BY L.D. McGill, DVM, Ph.D., DACVP Thank you for this referral. If the clinical or image interpretation does not parallel your findings or if I can be of any further assistance please contact me.

L.D. McGill, DVM,
Ph.D., DACVP

L.D. McGill, DVM, Ph.D., DACVP
8288 Top of the World Drive
Cottonwood Heights, UT 84121
ldmcgill.vetpath@gmail.com
cell: 801-865-1220

PATIENT
KJ Nelson

SPECIES
Canine

BREED
Lab Mix

SEX
Female Spayed

AGE
10.5y

WEIGHT
43 lbs

HOSPITAL NAME
Ruidoso Animal Clinic

REFERRING VET
Dr. Thurston

INVOICE NUMBER
675