



**DATE PRESENTING CLINICAL SIGNS**

2/17/23

Weight loss of 4lbs, low Albumin and liver mass found on AUS. Repeating USG FNA/cytology.  
PE: thinning truncal haircoat, esp caudal half of body.  
AUS: mixed echogenicity L caudal liver mass, apx. 6cm x 4cm.  
Alb 1.9

**INTERPRETED BY**

L.D. McGill, DVM,  
Ph.D, DACVP

**CYTOLOGY SUBMISSION**

Liver

**OBSERVATIONS**

Liver: Submitted are 5 excellent videos of cells collected from the liver in Charlotte. The hepatocytes demonstrate rather uniform sizes and shapes. There is slight anisokaryosis. There is minimal inflammation. In one or two sites there is a suggestion of fibrosis. The cellularity is definitely benign.

**PATIENT**

Charlotte Leary

**INTERPRETATION OF THE FINDINGS & FURTHER RECOMMENDATIONS**

Liver - Hepatocellular vacuolization and possible nodular hyperplasia with no evidence of malignancy.

**SPECIES**

Canine

**COMMENTS**

The cellularity includes good collections of hepatocytes. The hepatocytes are relatively normal with slight anisokaryosis. This could suggest the likelihood of nodular hyperplasia. You did collect some cells that were aggregated and uniform which are superficial mesothelial cells over the liver capsule. I was unable to suggest neoplasia or sepsis. The most severe process with this cellularity would be nodular hyperplasia. A guarded prognosis is warranted since the underlying process is not identified but there certainly is no suggestion of neoplasia.

**BREED**

King Charles Cavalier

**SEX**

Female Spayed

**AGE**

9y

**WEIGHT**

15 lbs

**HOSPITAL NAME**

Scanvet

**REFERRING VET**

Dr. Giroux

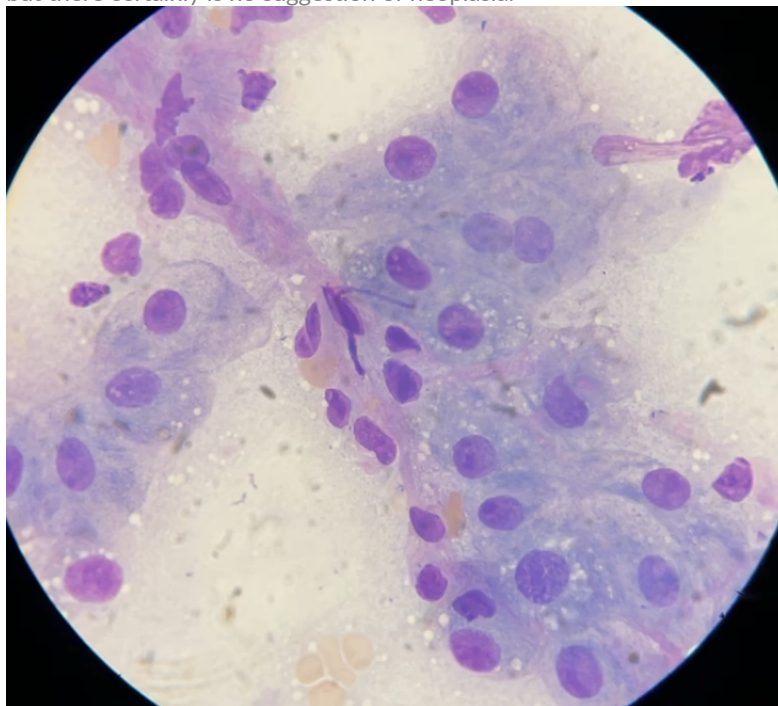


Image shows a representative collection of hepatocytes with vacuolization and mild anisokaryosis in the hepatocytes from Charlotte. There are cells suggestive of fibrosis and copper cannot be ruled out.

**INVOICE NUMBER**

896



**DATE** 2/17/23 The information and recommendations provided are based on the images presented by the referring veterinarian. No evaluation can be communicated regarding pathology that was not visible in the image/video clips provided.

**INTERPRETED BY** L.D. McGill, DVM, Ph.D., DACVP Thank you for this referral. If the clinical or image interpretation does not parallel your findings or if I can be of any further assistance please contact me.

L.D. McGill, DVM,  
Ph.D., DACVP

**L.D. McGill, DVM, Ph.D., DACVP**  
8288 Top of the World Drive  
Cottonwood Heights, UT 84121  
ldmcgill.vetpath@gmail.com  
cell: 801-865-1220

**PATIENT**  
Charlotte Leary

**SPECIES**  
Canine

**BREED**  
King Charles Cavalier

**SEX**  
Female Spayed

**AGE**  
9y

**WEIGHT**  
15 lbs

**HOSPITAL NAME**  
Scanvet

**REFERRING VET**  
Dr. Giroux

**INVOICE NUMBER**  
896