

DATE **PRESENTING CLINICAL SIGNS**
2/16/22 Recommend FNA of the liver mass.

CYTOLOGY SUBMISSION
Liver

INTERPRETED BY

L.D. McGill, DVM,
Ph.D, DACVP

OBSERVATIONS

Liver: Submitted are two excellent videos of cells collected from the liver in Panda. There are good aggregates of hepatocytes. Some of the hepatocytes are aggregated in irregular patterns. Other hepatocytes demonstrate vacuolization of the cytoplasm. Other aggregates are slightly granulated. There are scattered inflammatory cells in the red blood cell smear which include lymphocytes and neutrophils. Malignant criteria are not identified.

PATIENT

Panda Dolan

INTERPRETATION OF THE FINDINGS & FURTHER RECOMMENDATIONS

Liver - Moderate multifocal hepatocellular vacuolization and granularity with mild inflammation.

SPECIES **COMMENTS**

Canine

The cellularity in the hepatocytes suggest the likelihood of hepatocellular vacuolization which can occur secondary to metabolic liver changes. This is a common finding in the liver associated with steroid hepatopathy. This could occur if there is an adrenal gland tumor. This could occur secondarily to other problems including inflammation in the intestine and pancreas. There is no suggestion of malignancy or sepsis. A guarded prognosis is warranted since a specific disease process has not been identified at this time.

BREED

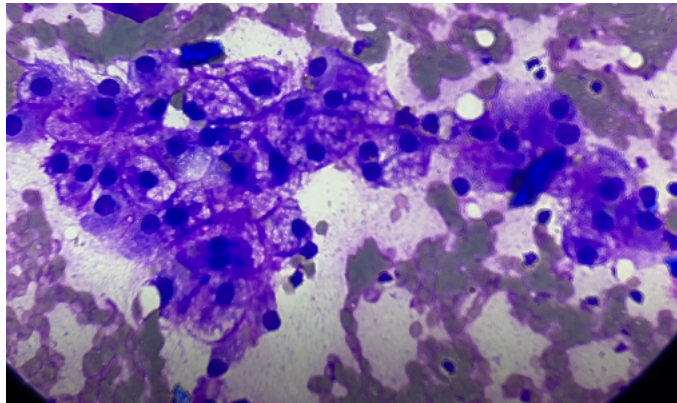
Kelpie x

SEX

Female Spayed

AGE

11y



WEIGHT

77.3 lbs

Image shows hepatocytes with vacuolization aggregated irregularly from the liver in Panda. Inflammatory cells are present around the hepatocytes.

The information and recommendations provided are based on the images presented by the referring veterinarian. No evaluation can be communicated regarding pathology that was not visible in the image/video clips provided.

HOSPITAL NAME

Pleasant Hill Animal
Hospital

Thank you for this referral. If the clinical or image interpretation does not parallel your findings or if I can be of any further assistance please contact me.

REFERRING VET

Dr. Seyler

L.D. McGill, DVM, Ph.D., DACVP
8288 Top of the World Drive
Cottonwood Heights, UT 84121
ldmcgill.vetpath@gmail.com
cell: 801-865-1220

INVOICE NUMBER

673



DATE

2/16/22

INTERPRETED BY

L.D. McGill, DVM,
Ph.D, DACVP

PATIENT

Panda Dolan

SPECIES

Canine

BREED

Kelpie x

SEX

Female Spayed

AGE

11y

WEIGHT

77.3 lbs

HOSPITAL NAME

Pleasant Hill Animal
Hospital

REFERRING VET

Dr. Seyler

INVOICE NUMBER

673