



**DATE PRESENTING CLINICAL SIGNS**

2/16/2022

Hx of mast cell removal from leg; US showed mottled spleen; R/O mast cell vs benign vs other

**CYTOLOGY SUBMISSION**

Spleen

**INTERPRETED BY**

L.D. McGill, DVM,  
Ph.D., DACVP

**OBSERVATIONS**

Spleen: Submitted are 6 excellent videos of excellent to moderate cellular collections from the spleen in Levi. The cellularity is mixed throughout all of the videos. There are collections of neutrophils, scattered lymphocytes and good collections of macrophages. There are some aggregates of macrophages and spindloid cells. Mast cells were not identified.

**PATIENT**

Levi Whittaker

**INTERPRETATION OF THE FINDINGS & FURTHER RECOMMENDATIONS**

Spleen - Mixed cell collection suggesting mild inflammation and fibrohistiocytic nodules with no mast cells identified.

**SPECIES**

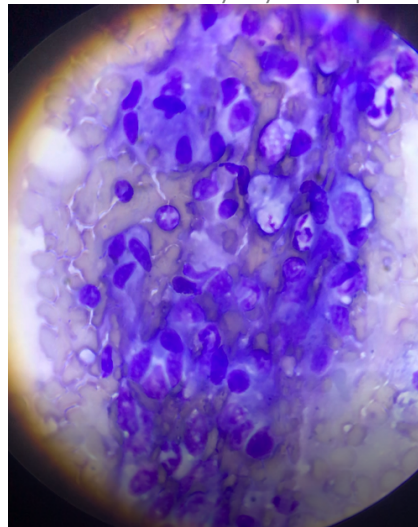
Canine

**COMMENTS**

The cellularity in this collection is representative of a slightly reactive spleen but no evidence of malignancy. With no mast cells identified, the lesion on the leg is hopefully limited to that location. I am unable to identify any other specific pathology.

**BREED**

Pit Bull



**SEX**

Male Neutered

**AGE**

5y

**WEIGHT**

104lbs

Image shows a group of cells suggesting a fibrohistiocytic nodule. No mast cells were identified.

**HOSPITAL NAME**

Animal Care Centers  
Flanders

The information and recommendations provided are based on the images presented by the referring veterinarian. No evaluation can be communicated regarding pathology that was not visible in the image/video clips provided.

Thank you for this referral. If the clinical or image interpretation does not parallel your findings or if I can be of any further assistance please contact me.

**REFERRING VET**

Dr. Hallihan

L.D. McGill, DVM, Ph.D., DACVP  
8288 Top of the World Drive  
Cottonwood Heights, UT 84121  
ldmcgill.vetpath@gmail.com  
cell: 801-865-1220

**INVOICE NUMBER**

671



**DATE**

2/16/2022

**INTERPRETED BY**

L.D. McGill, DVM,  
Ph.D, DACVP

**PATIENT**

Levi Whittaker

**SPECIES**

Canine

**BREED**

Pit Bull

**SEX**

Male Neutered

**AGE**

5y

**WEIGHT**

104lbs

**HOSPITAL NAME**

Animal Care Centers  
Flanders

**REFERRING VET**

Dr. Hallihan

**INVOICE NUMBER**

671