



DATE PRESENTING CLINICAL SIGNS

2/16/22

Coarse splenomegaly; R/O infiltrative disease vs other. Continued GI issues and wt loss.

CYTOLOGY SUBMISSION

Spleen

INTERPRETED BY

L.D. McGill, DVM,
Ph.D, DACVP

OBSERVATIONS

Spleen: Submitted are 4 excellent videos of excellent to moderate collections of cells from the spleen in Cloudy. The cellularity in one video includes large numbers of round cells that are aggregated. These cells are demonstrating slightly variable nuclei and anisocytosis. They appear to be lymphoid cells. In the majority of the videos there is a mixed cell collection including neutrophils and large numbers of eosinophils. Macrophages and scattered lymphocytes are identified in those videos.

PATIENT

Cloudy Manjarres

INTERPRETATION OF THE FINDINGS & FURTHER RECOMMENDATIONS

Spleen - Chronic suppurative and eosinophilic splenitis with one field suggesting increased numbers of lymphoid cells.

SPECIES

Feline

COMMENTS

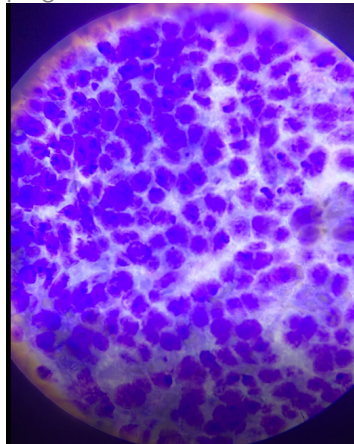
The cellularity in this collection is somewhat irregular. In the first video, there are large numbers of lymphoid cells which could suggest the possibility of an early lymphoma. That cellularity is not confirmed in the other videos. The other videos suggest eosinophilic infiltration which could also relate to what is occurring in the intestine. There could be any eosinophilic enteritis or diffuse eosinophilic infiltration in Cloudy. These slides could be sent out for PARR testing to confirm the presence of neoplasia or rule it out or splenectomy can be considered. Treatment for eosinophilic inflammatory bowel disease can also be considered prior to any surgical intervention. A guarded prognosis is warranted.

BREED

DSH

SEX

Male Neutered



AGE

6y

WEIGHT

9.5 lbs

HOSPITAL NAME

Animal Care Center
Flanders

Image shows a group of lymphocytes demonstrated on 1 video. There is anisocytosis and anisokaryosis in these cells.

REFERRING VET

Dr. Casulli

The information and recommendations provided are based on the images presented by the referring veterinarian. No evaluation can be communicated regarding pathology that was not visible in the image/video clips provided.

Thank you for this referral. If the clinical or image interpretation does not parallel your findings or if I can be of any further assistance please contact me.

INVOICE NUMBER

672



DATE L.D. McGill, DVM, Ph.D., DACVP
8288 Top of the World Drive
Cottonwood Heights, UT 84121
ldmcgill.vetpath@gmail.com
cell: 801-865-1220

INTERPRETED BY

L.D. McGill, DVM,
Ph.D., DACVP

PATIENT

Cloudy Manjarres

SPECIES

Feline

BREED

DSH

SEX

Male Neutered

AGE

6y

WEIGHT

9.5 lbs

HOSPITAL NAME

Animal Care Center
Flanders

REFERRING VET

Dr. Casulli

INVOICE NUMBER

672